FLORIDA SOCIETY OF ORAL AND MAXILLOFACIAL SURGEONS

Annual Meeting

October 26, 2018

THE ROLE OF EFFECTIVE/SAFE NERVE ALLOGRAFTS

MR DETECTION IN THE DIAGNOSIS AND MANAGEMENT OF TRAUMATIC AND PLANNED TRIGEMINAL NERVE INJURIES

John R. Zuniga DMD, MS, PhD
Robert V. Walker DDS Chair in Oral and Maxillofacial Surgery
Professor, Departments of Surgery and Neurology & Neurotherapeutics
University of Texas Southwestern
Parkland Hospital
Children's Medical Center
Dallas, Texas

FSOMS Mission

The mission of the Florida Society of Oral & Maxillofacial Surgeons is to improve the health of Florida residents through high practice standards, public and professional advocacy, ethical behavior, and to support its members through continuous professional education and advancement of the specialty.

Established 1960

FSOMS



John Zuniga DMD PhD
Robert V. Walker DDS Chair in Oral and Maxillofacial Surgery


THE UNIVERSITY OF TEXAS
Southwestern Medical Center
AT DALLAS

The New Parkland
August 20, 2015

FLORIDA SOCIETY OF ORAL AND MAXILLOFACIAL SURGEONS

THE ROLE OF EFFECTIVE/SAFE NERVE ALLOGRAFTS

FSOMS Mission

The mission of the Florida Society of Oral & Maxillofacial Surgeons is to improve the health of Florida residents through high practice standards, public and professional advocacy, ethical behavior, and to support its members through continuous professional education and advancement of the specialty.

Established 1960

FS OMS

NERVE REPAIR PRINCIPLES/TECHNIQUES

- ACCESS PHASE
  - Goal= allow the ability to complete 2nd and 3rd phases (which affects outcome)
    - Exposure should always include normal nerve tissue on proximal and distal ends
    - Exposure of nerve length to allow preparation and mobilization (recommend 1 cm)
    - Provide unobstructed view by adequate retraction and retention of adjacent tissues
    - Ensure a surgical plane for the use of an operating microscope (or loupes)
- PREPARATION PHASE
  - Goal=identify normal nerve on the proximal and distal ends
    - Release mesoneurium from scar, etc. to explore the epineurial tissues for pathologic tissue (neuroma, scar, etc)
    - Identify normal fascicular pattern (fascicular patterns) from abnormal (intrafascicular scar, etc)
    - If abnormal, resect the ends till normal nerve fascicles identified (axon white, plump, protruding with interfascicular bleeding)
- MICROSURGERY PHASE
  - Goal= approximation of normal nerve tissues under no tension
    - If 5mm or less of nerve gap then direct neurorraphy
    - If >5mm of nerve gap then neurorraphy with nerve graft (autograft, allograft or conduit)



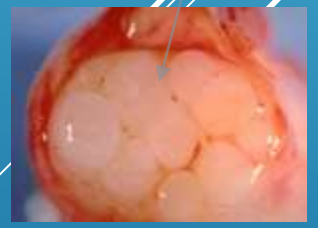

Zuniga JR, Zenn MR: Principles of Microsurgery, Clin Trials in Orofacial Neurotrama. OMS Clin N A, 13:331-342, 2001

NERVE REPAIR PRINCIPLES/TECHNIQUES

- ACCESS PHASE OPTIONS
  - Transoral, buccal decortication
  - Extraoral, buccal decortication
  - Sagittal osteotomy
- PREPARATION PHASE OPTIONS
  - Loupes
  - Surgical microscope
- MICROSURGICAL PHASE OPTIONS
  - Direct neurorraphy with 8-0 nylon
  - Connector Assisted Repair (CAR)
  - Neurorraphy with autograft, allograft or conduit



SURGERY

INFERIOR ALVEOLAR NERVE, 1986- 2008

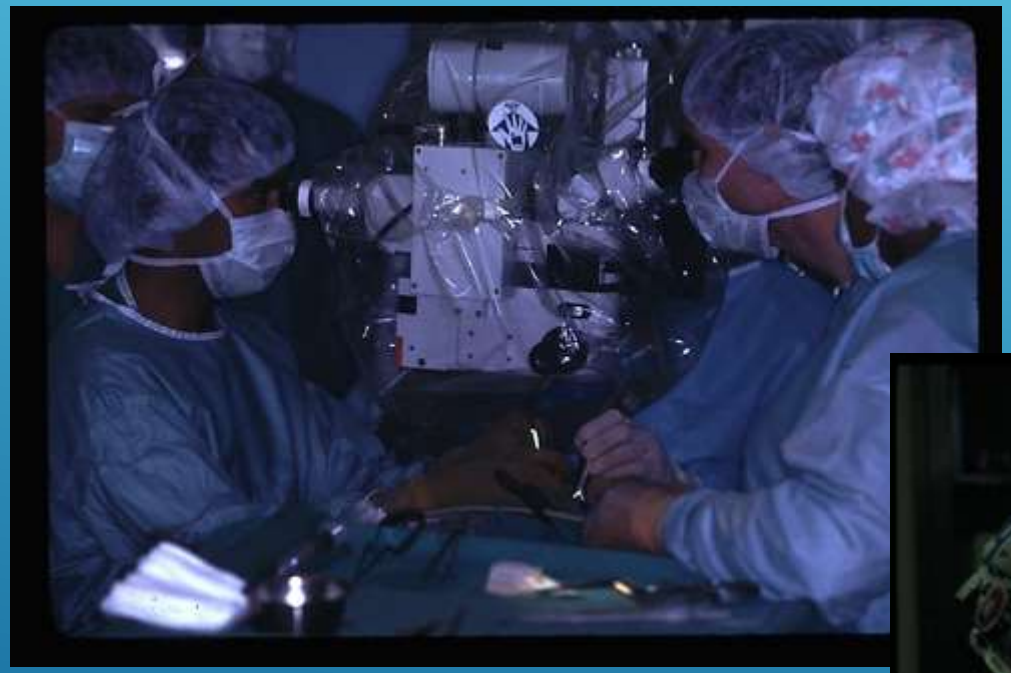

IAN: ACCESS PHASE

1986-2008

IAN: ACCESS PHASE

1986-2008

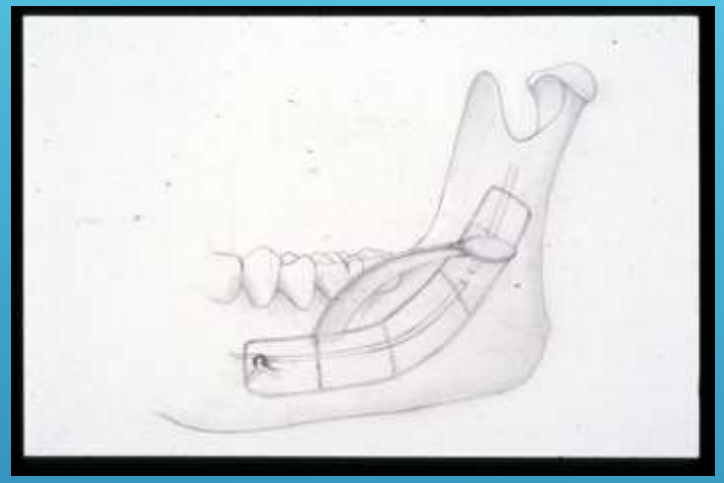

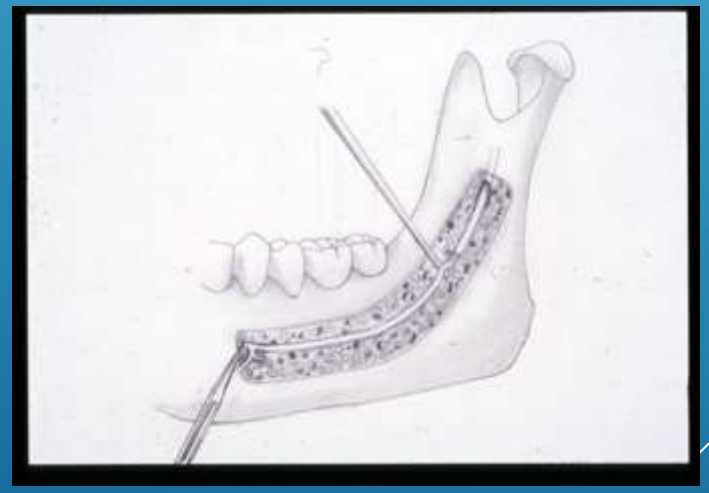

IAN: PREPARATION AND MICROSURGERY PHASE

1986-2008

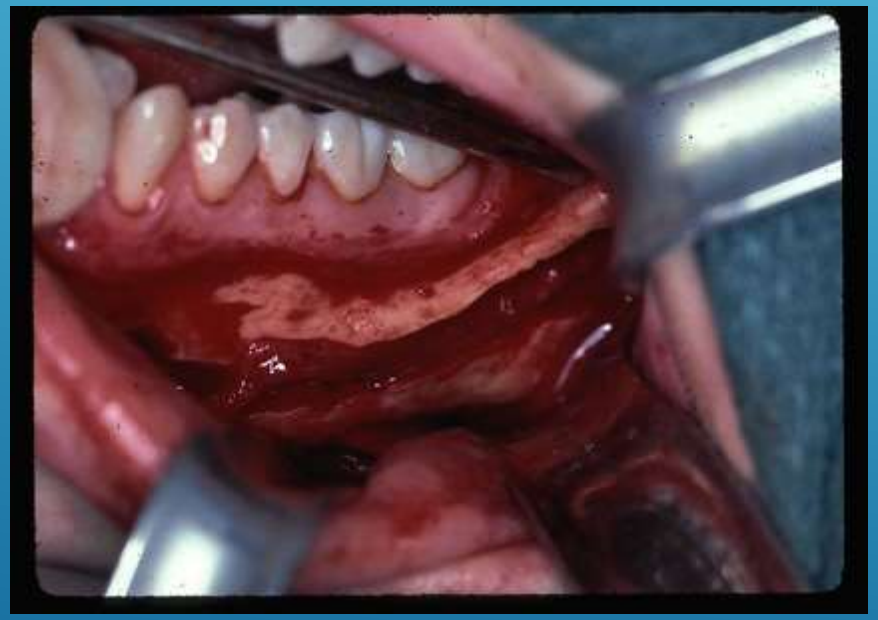

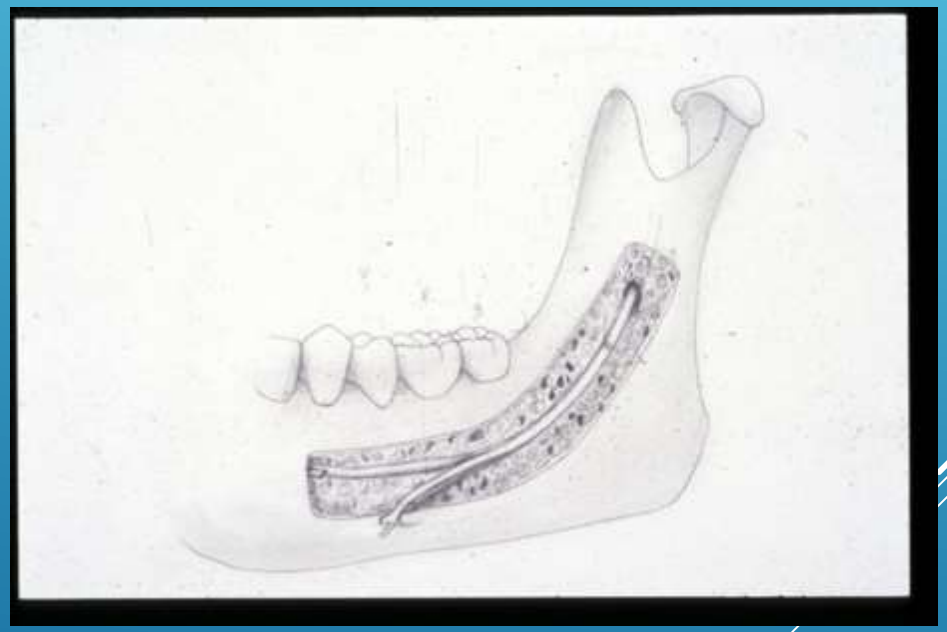


R
L
KODAK 8000 System

IAN

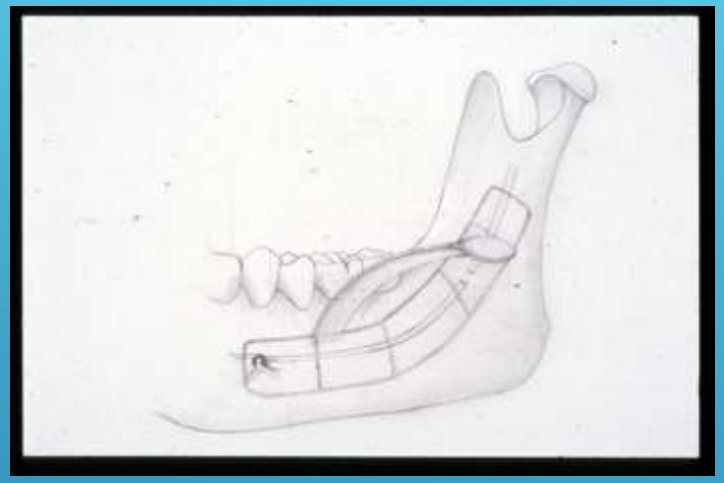

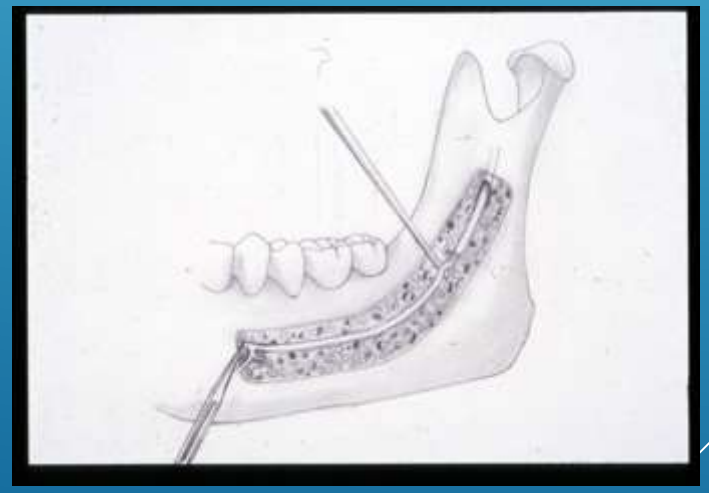

AVANCE Nerve Graft

Repairing Nerve with Nerve

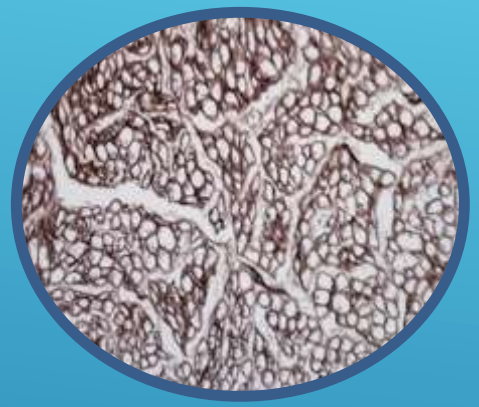

ECM Maintained
Laminin Retained
Noncellular Inhibitors Cleared





Handles similar to autograft

Decellularized Nerve Graft
Does not cause Tissue Rejection

Ability to Match
Nerve Stump Diameter

PROCESSED NERVE ALLOGRAFT

Human Peripheral Nerve Tissue (Avance® Nerve Graft, AxoGen, Inc)

- 3-Dimensional ECM scaffold
- Decellularized
- Pre-Degenerated
- Sterilized
- Preserved Architecture
  - Epineurium
  - Perineurium
  - Fascicles
  - Endoneural tubes
  - Microvasculature

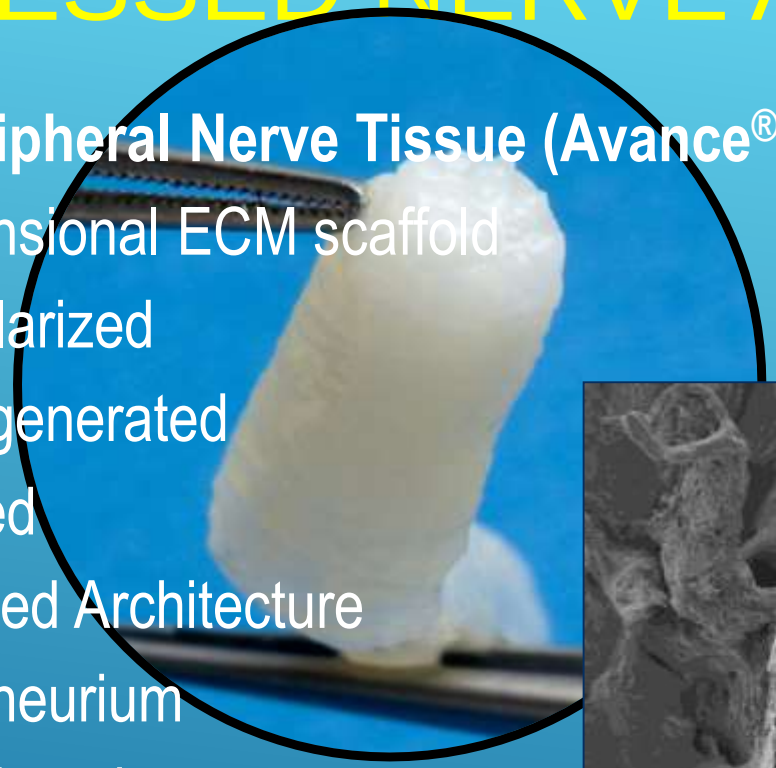

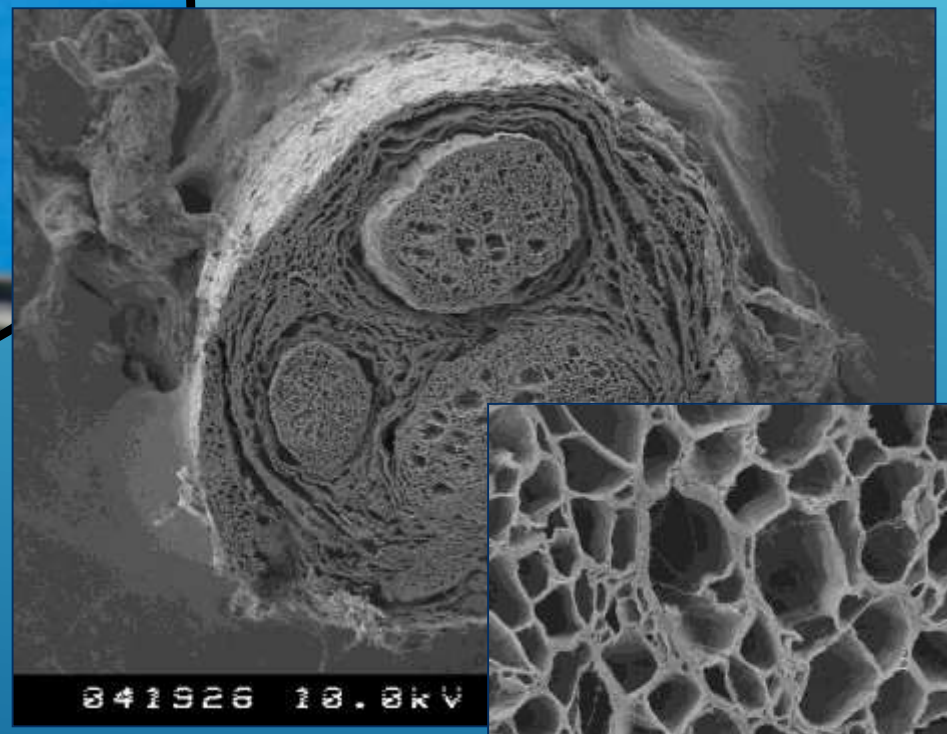


R
L
KODAK 8000 System

Left proximal IAN

Left distal IAN at foramen

Right proximal IAN

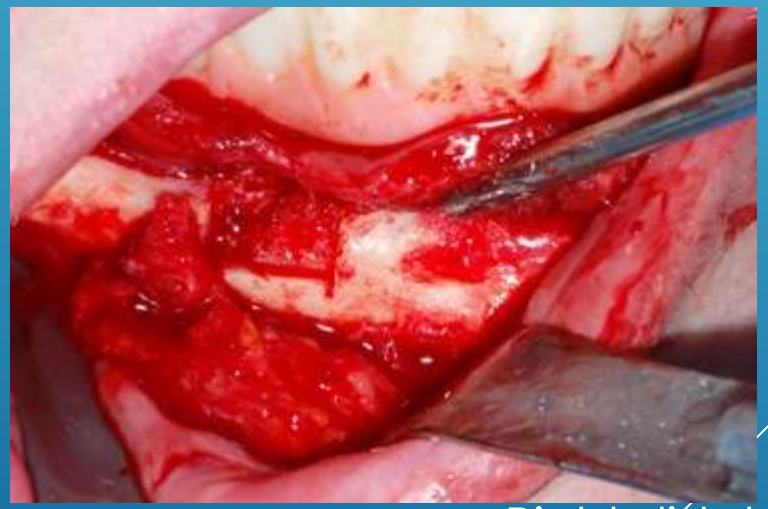

Right distal IAN at foramen

Left proximal repair with AVANCE

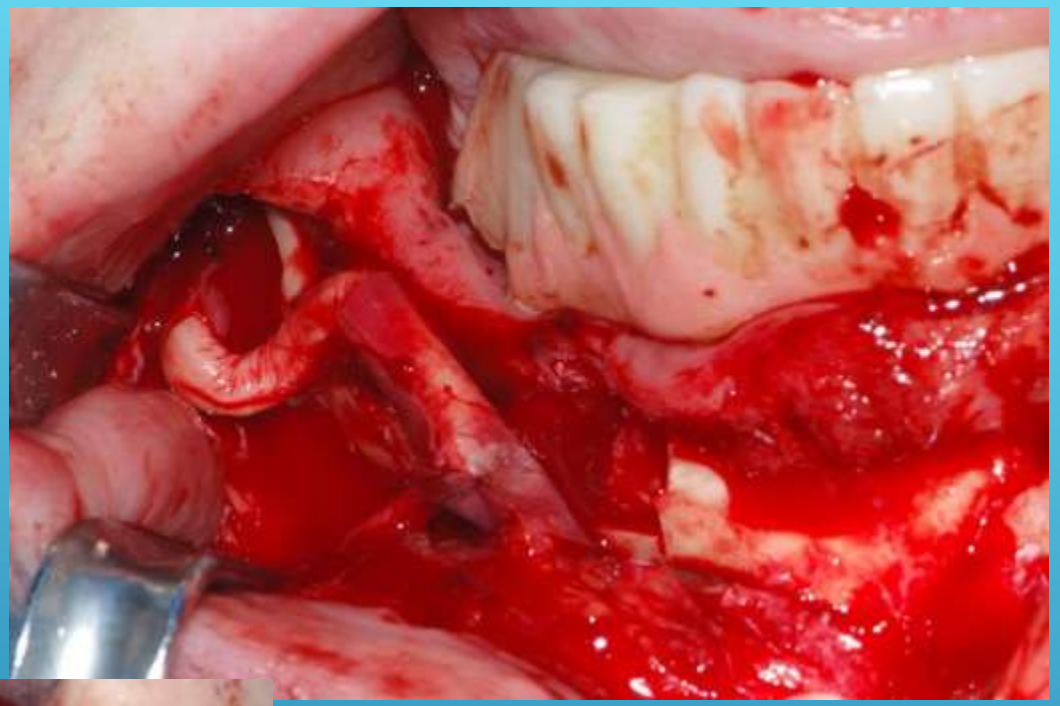

Right AVANCE and Axoguard

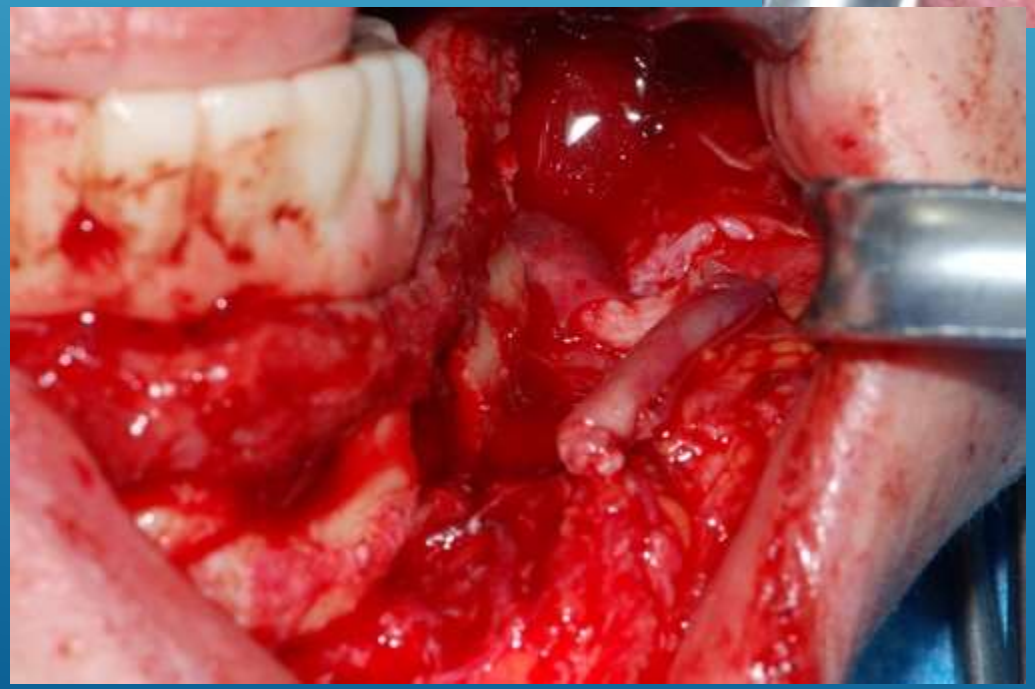

Left AVANCE and Axoguard

AxoGen® Family of Products

Avance® Nerve Graft

THE NATURAL CONNECTION

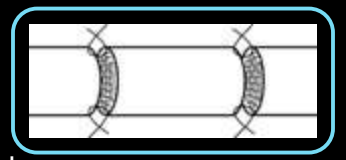

- Bridge gaps up to 70mm
- Cable grafting (alone or in combination with autograft)
- Bridge a partially severed nerve

AXOGUARD™ Nerve Connector

ALIGN & CONNECT

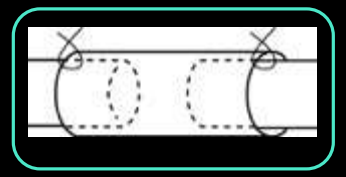

- Bridge gaps up to 5mm
- Coaptation aid for direct repair, grafting, or cable grafting
- Reinforce a coaptation sit

AXOGUARD™ Nerve Protector

WRAP & PROTECT

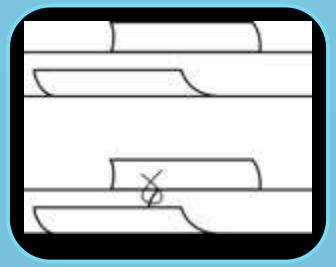

- Wrap injured nerves up to 40mm
- Minimize risk of entrapment in compressed nerves
- Protect partially transected nerves
- Reinforce a coaptation site

AXOGUARD® NERVE PROTECTOR AND AXOGUARD® NERVE CONNECTOR

Semi-Translucent

Conformable to nerve

Easily cut and sutured

AXOGUARD® NERVE PROTECTOR AND AXOGUARD® NERVE CONNECTOR

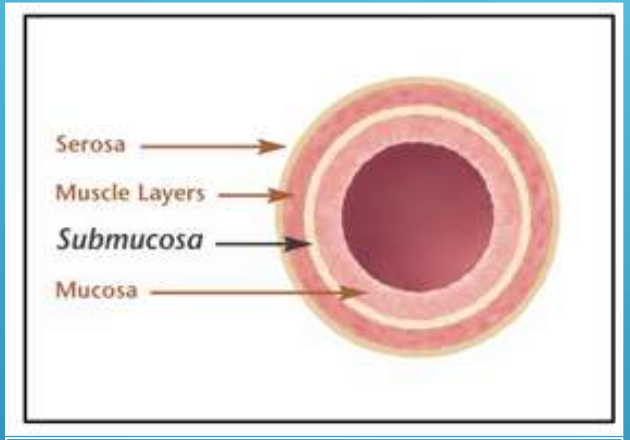

Proprietary Processing & Terminal Sterilization

- Not reconstituted or chemically cross-linked
- 4 layers for added strength
- Semi-Translucent





Processing retains 3-D structure & composition of biological ECM[6]

IAN

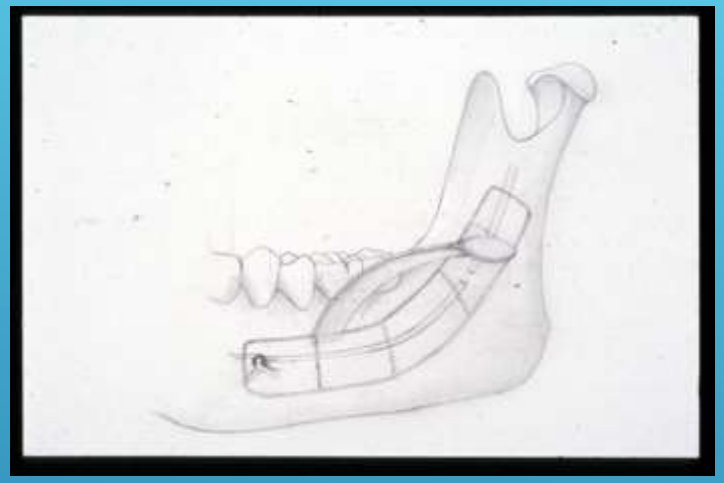

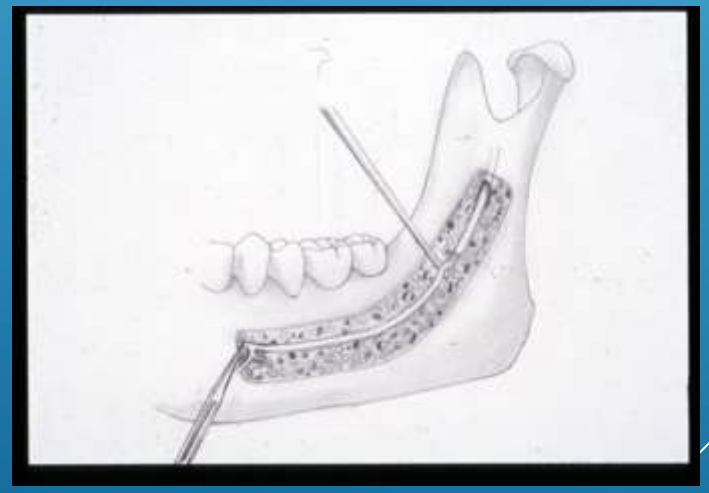

LN

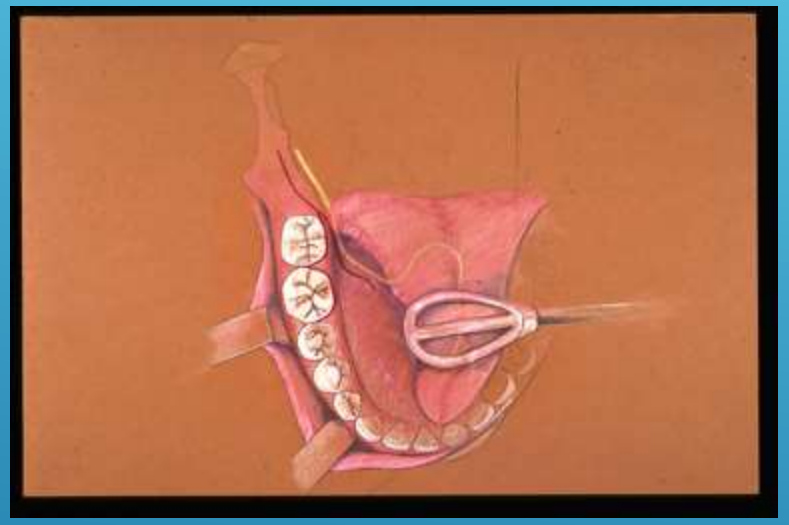

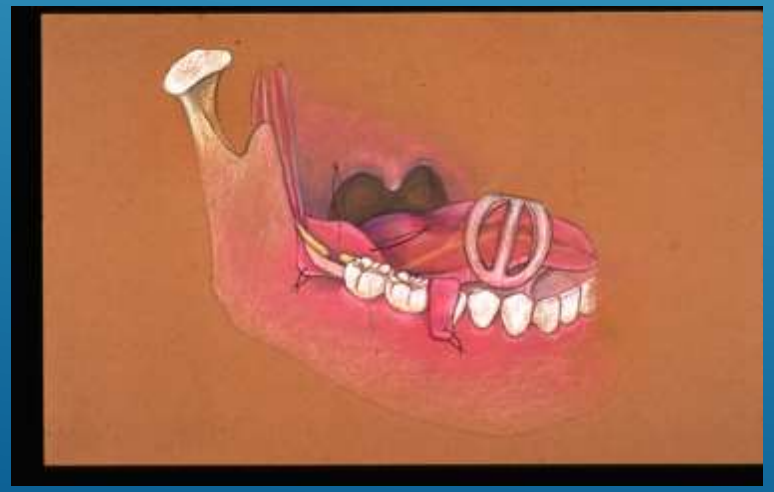

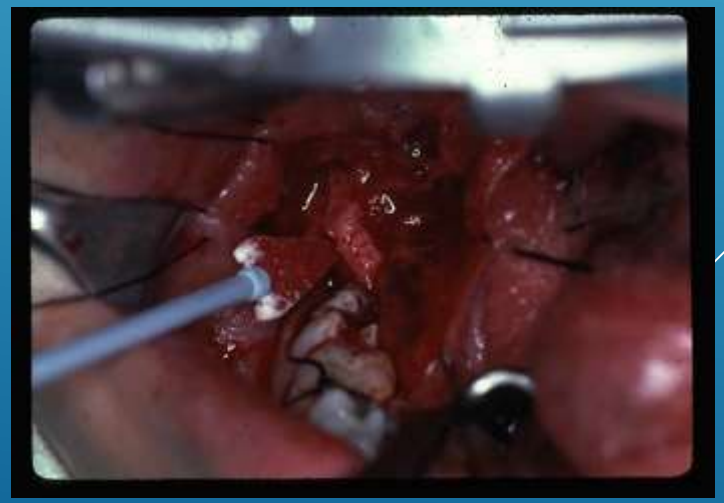

LN

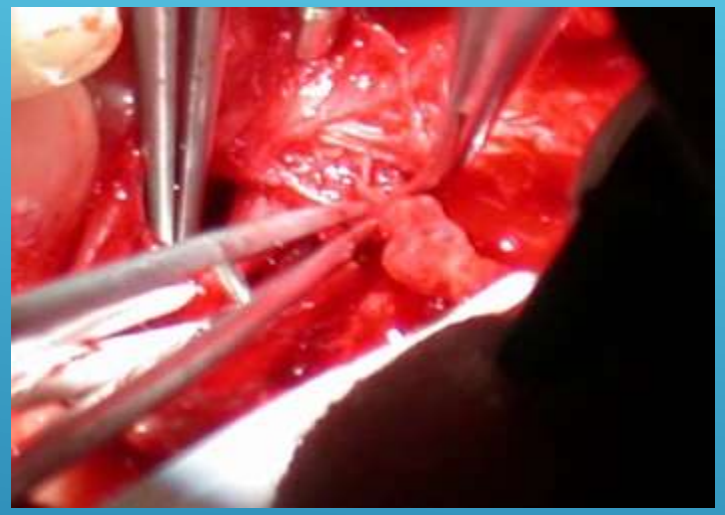

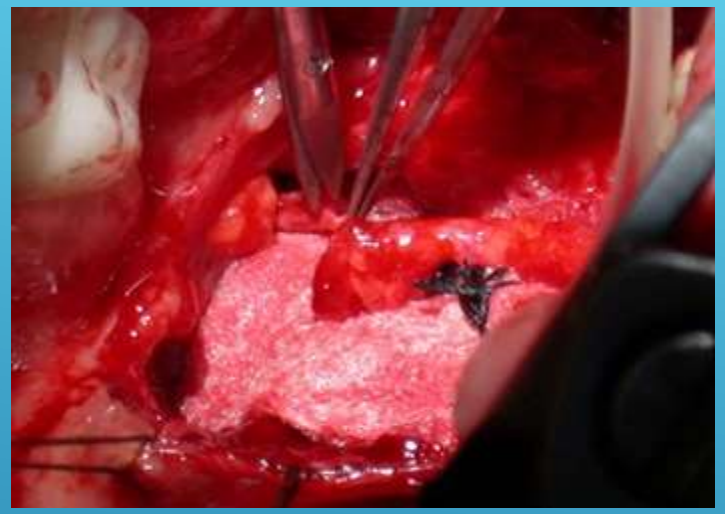

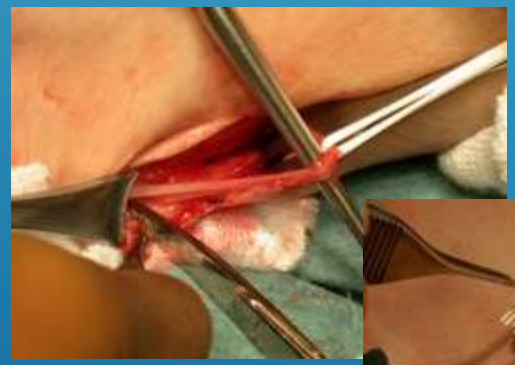

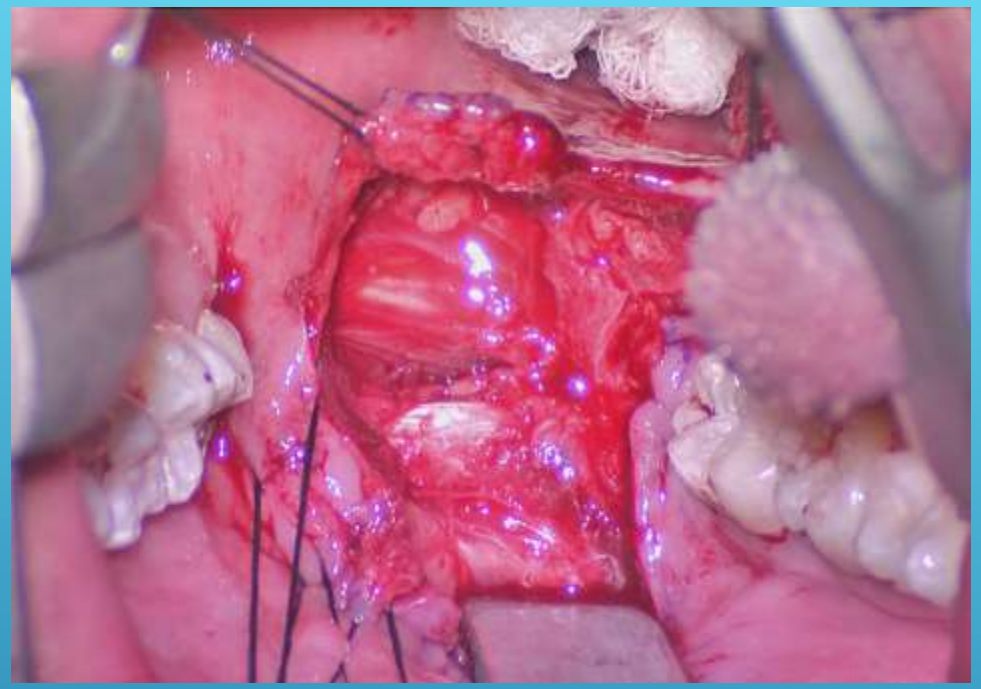

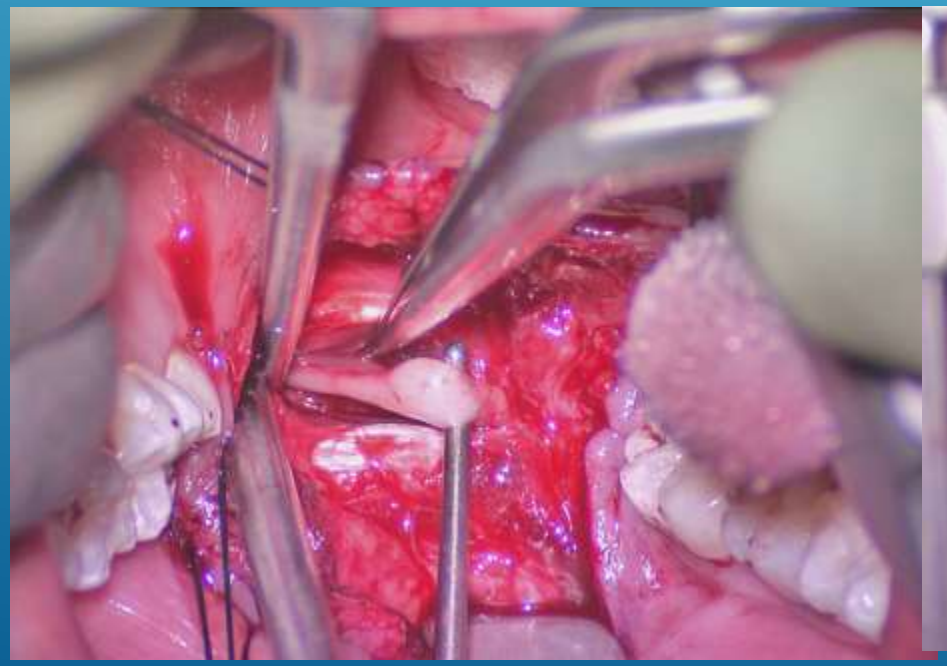

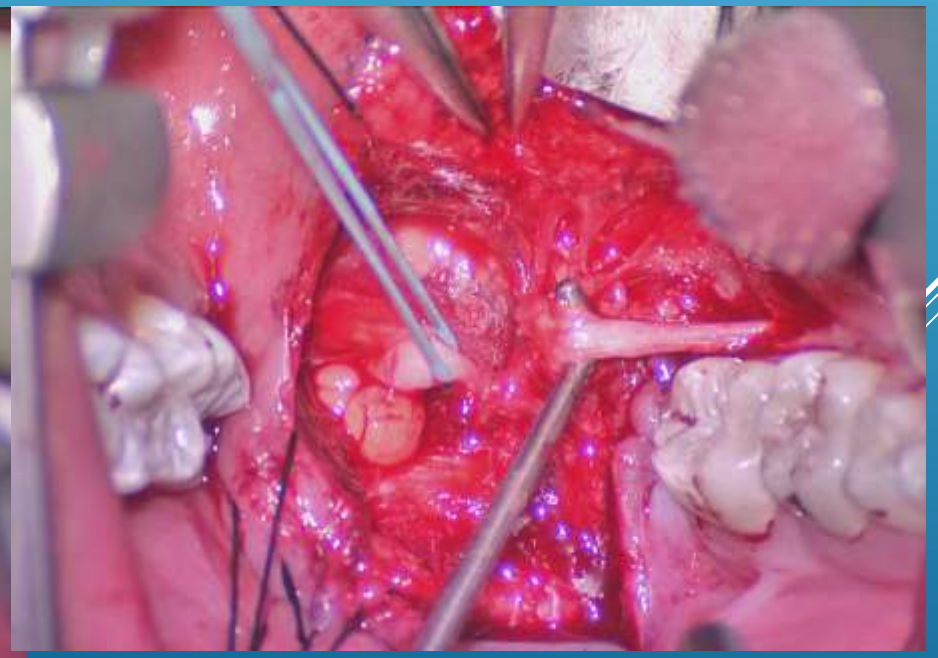

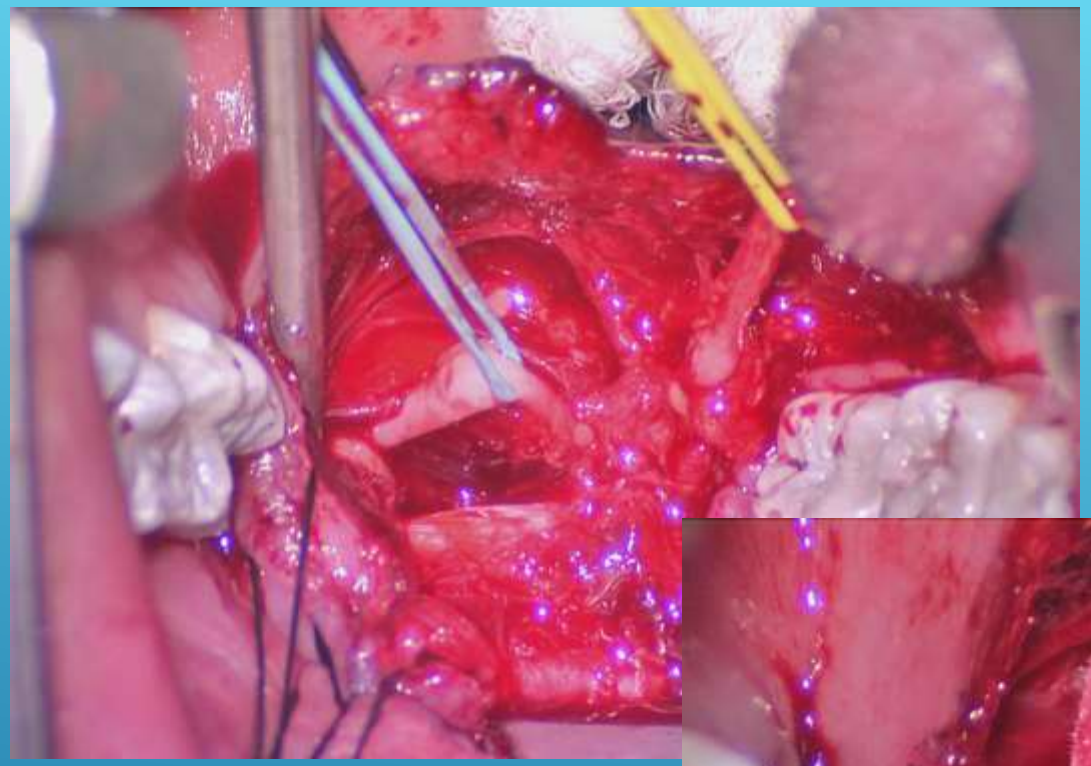

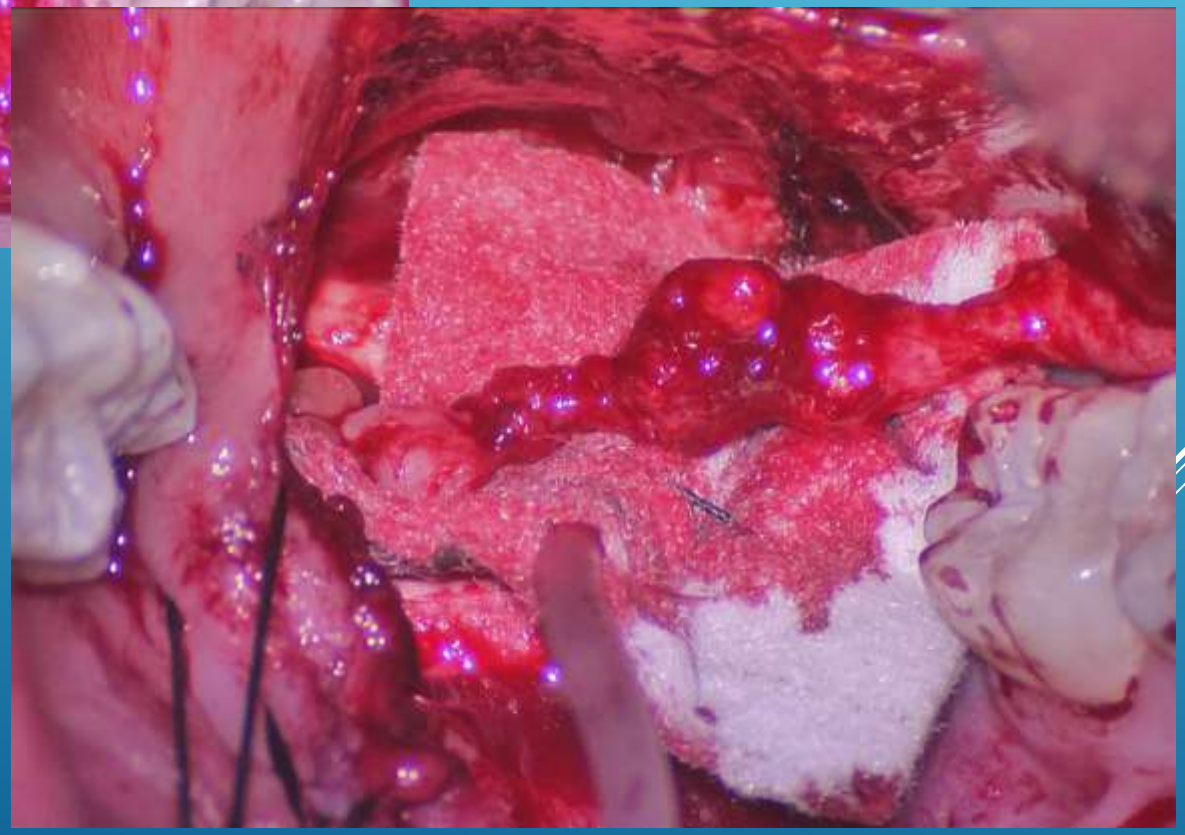

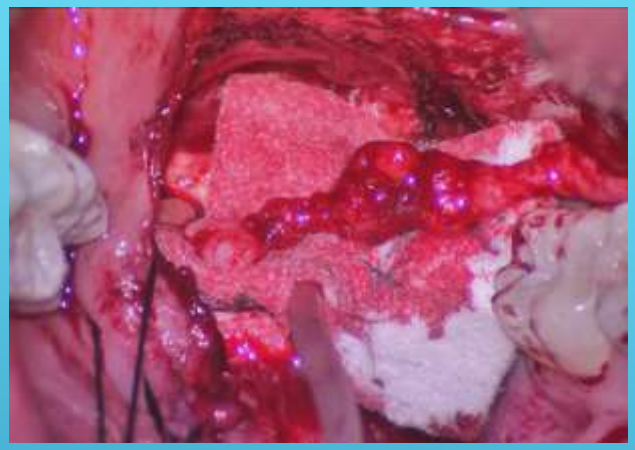

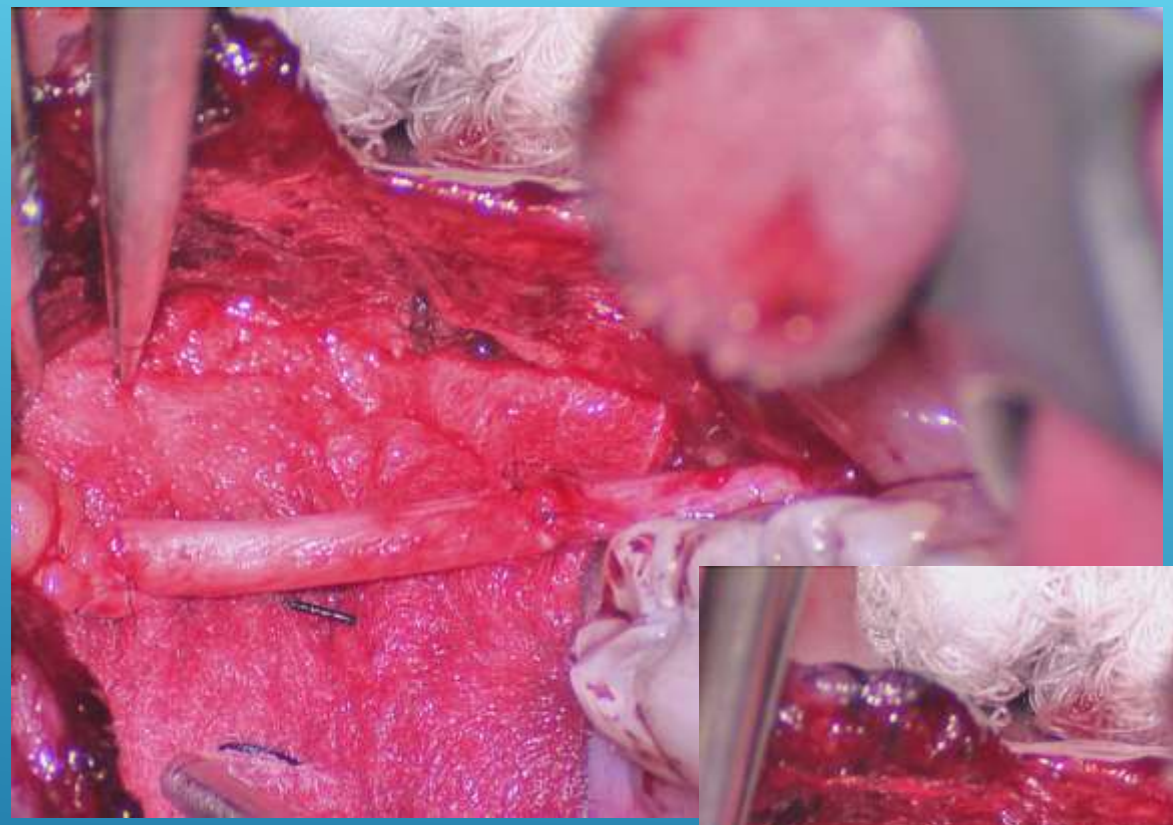

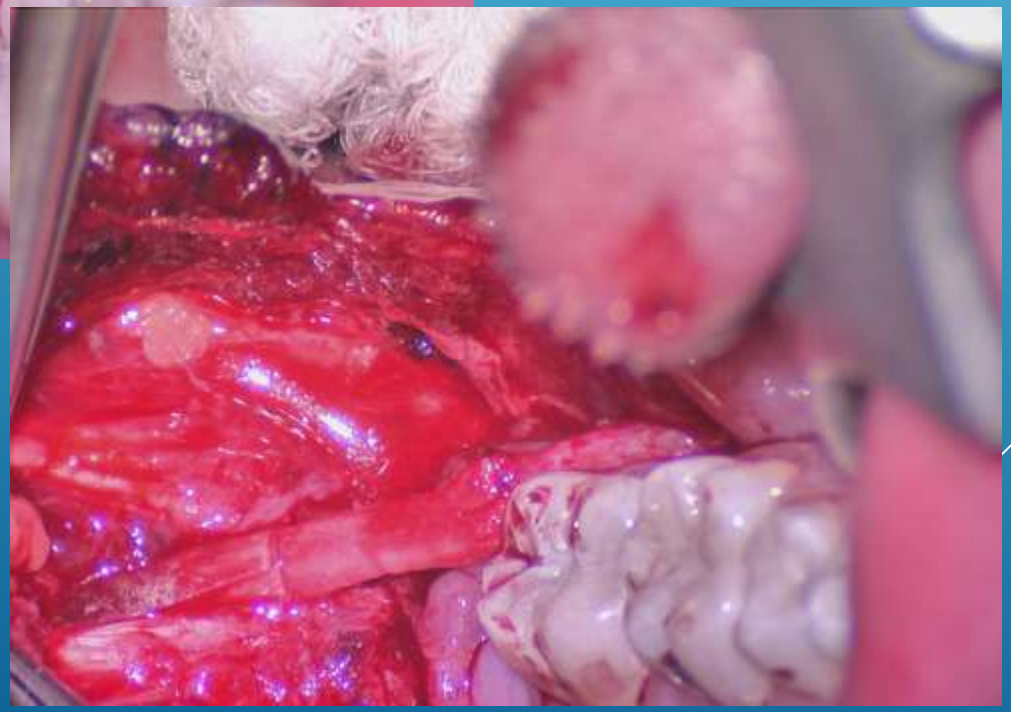

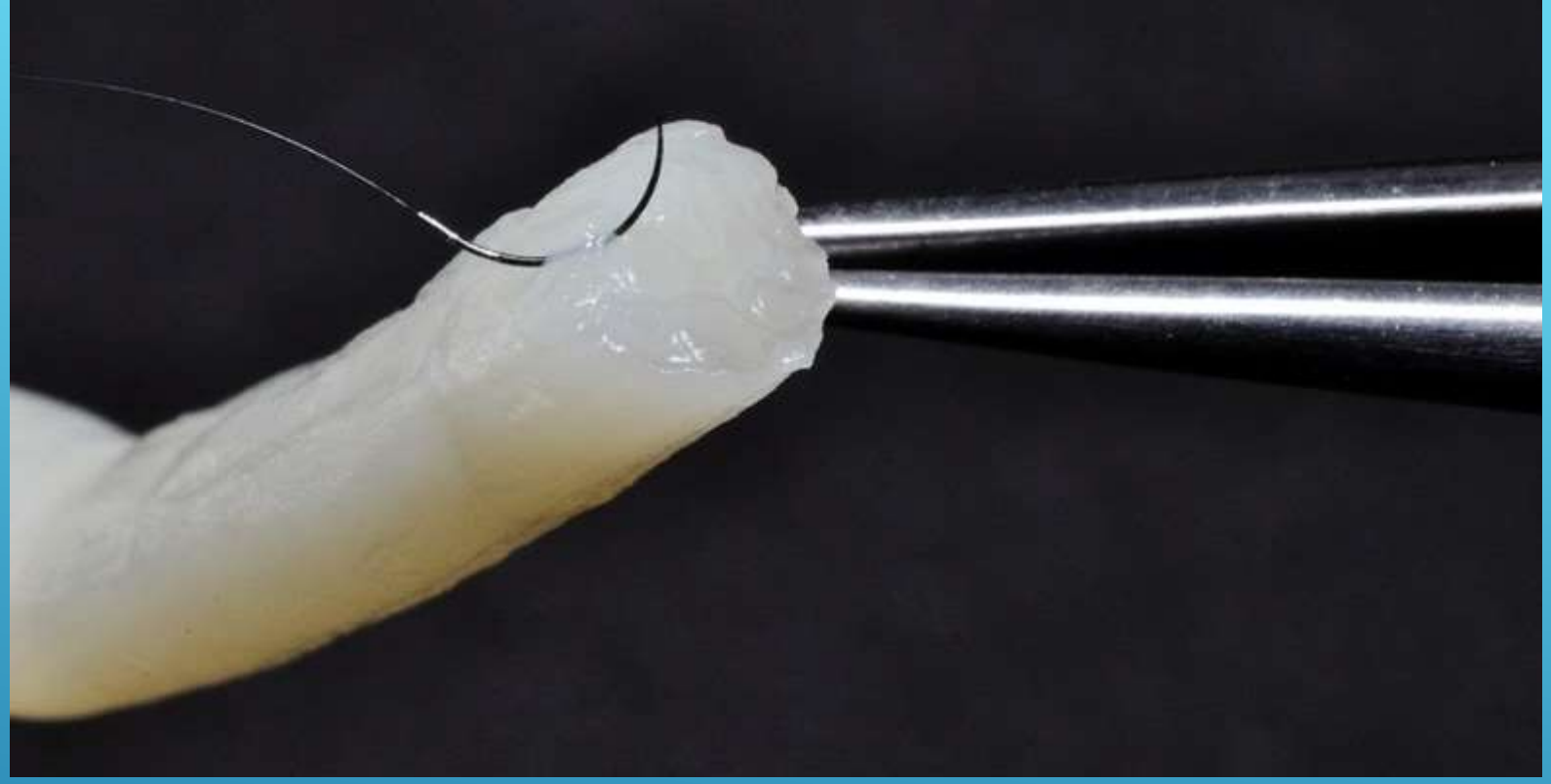

vs.


AxoGuard®
NerveConnector
Forced misalignment and fascicular mismatch may occur when nerve stumps are repaired directly with suture.[1,2]*
* Epineurium and connective tissue have been removed for illustration purposes.
Use of AxoGuard® Nerve Connector minimizes opportunity for fascicular mismatch and may improve outcomes.[3,4]*

OUTCOMES FOR RECONSTRUCTING THE TRIGEMINAL NERVE WITH AVANCE® NERVE GRAFT

ZUNIGA JR, JOMS 73:734-744, 2015.

- **20 nerve graft repairs in 18 patients from 2008 to 2012**
- **Follow up for minimum of 6 months**
  - Useable data = 17
  - Lost to follow up or not completing 6 months = 3
- **Sensory Analysis = NST Sensory Impairment Score**
  - Both tests in level A within normative limits= Normal (0)
  - Level A abnormal, Level B & C normal = Mild (1)
  - Level A and B abnormal, Level C normal = Moderate (2)
  - Level A, B and C abnormal, but elevated = Severe (3)
  - Level A,B and C abnormal, and absent = Complete (4)

UT SOUTHWESTERN MEDICAL CENTER

DEMOGRAPHICS IN OUTCOME POPULATION

Attribute	Variable	N	Mean
Gender	Female	9	n/a
	Male	8	n/a
Age (years)	<29	7	
	30-49	7	***30.3±15**
	50-86	4	
Nerve Location	Lingual	11	n/a
	Inferior Alveolar	6	n/a
Time to Repair (days)	Acute (0-21)	5	
	Delayed (22-90)	3	***217±199**
	Chronic (>91)	9	
Mechanism of Injury	3rd molar	10	n/a
	BSSO	2	n/a
	Tumor	4	n/a
	Implant	2	n/a
Gap Length (mm)	5-10	0	
	11-30	11	***30±24**
	31-70	6	
Injury Classification	Normal*	4	n/a
	Class 4	12	n/a
	Class 5	1	n/a

UT SOUTHWESTERN MEDICAL CENTER

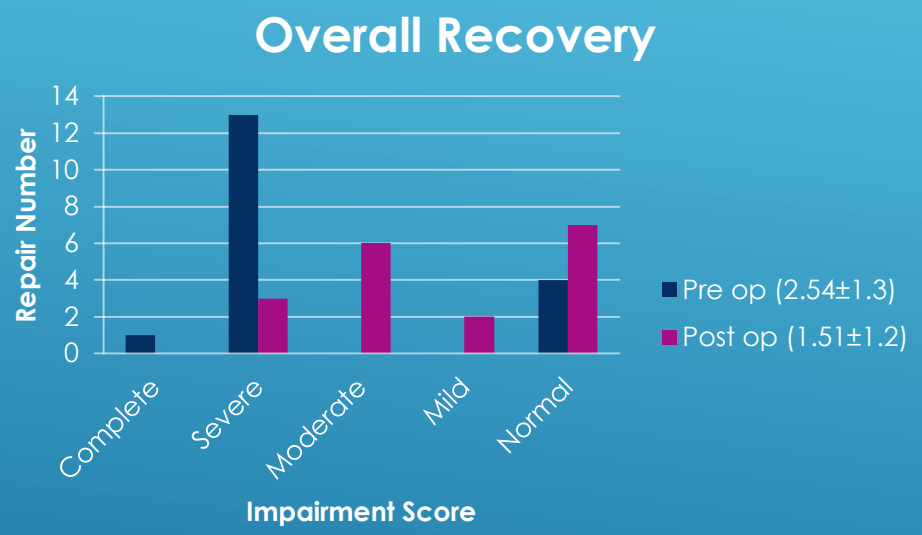

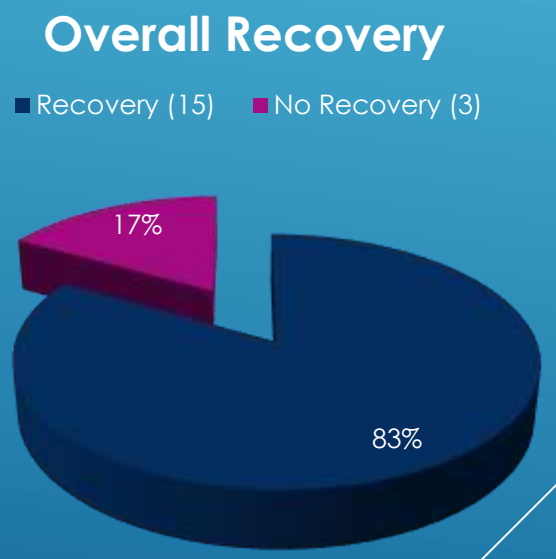

OVERALL RECOVERY (N=17)

UT SOUTHWESTERN MEDICAL CENTER

OUTCOME RECOVERY RESPONSE TO AVANCE® NERVE GRAFT

Attribute	N	PreOP NST	PostOp NST	T value	P value
Age <29	7	2.4±1.1	1.5±1.2	1.55	0.11
30-49	7	2.28±1.4	2.2±1.4	1.14	0.16
50-86	4	2.6±1.1	1.8±0.7	0.95	0.2
Mechanism 3rd molar	11	3.1±0.1	1.5±1.1	4.2	0.01*
BSSO	2	3	1±1	3.8	0.01*
Tumor	4	0	0	n/a	n/a*
Implant	2	3	1.7±0.1	2.7	0.05*

UT SOUTHWESTERN MEDICAL CENTER

RECOVERY BY NERVE GAP

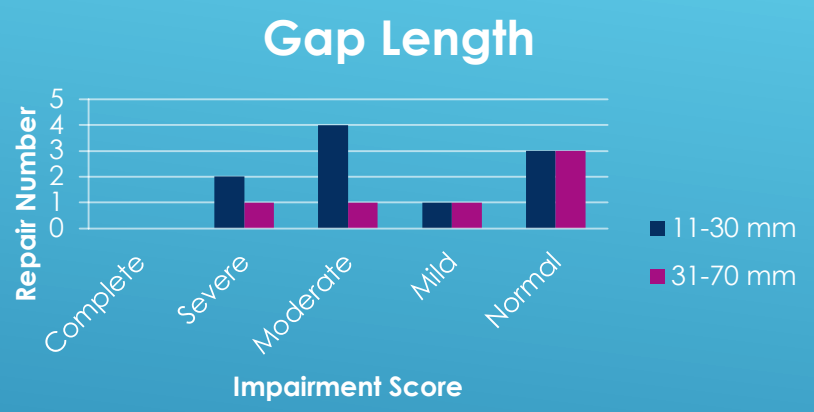

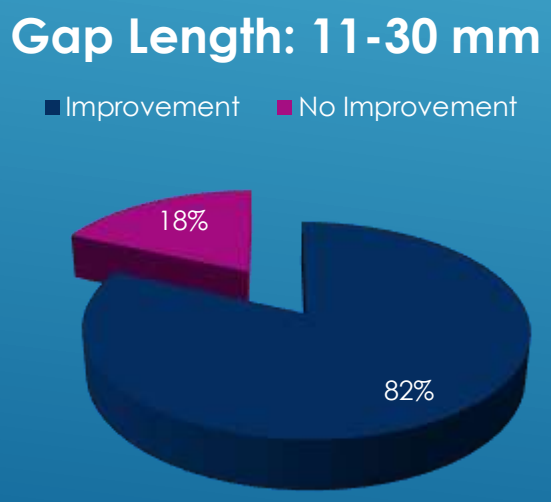

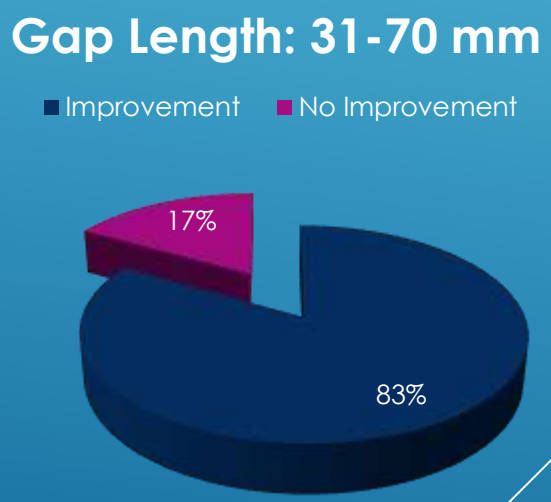

UT SOUTHWESTERN MEDICAL CENTER

RECOVERY BY TIME TO REPAIR

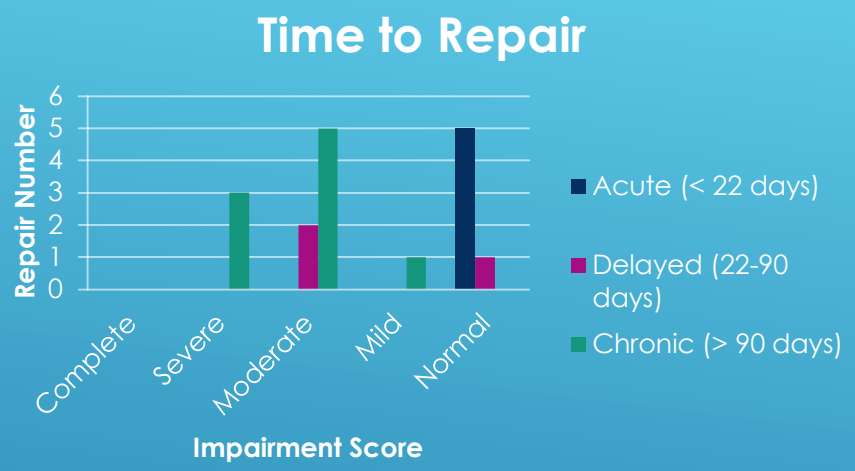

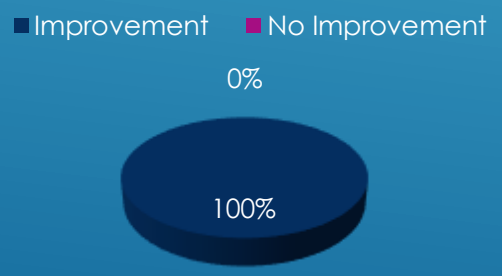

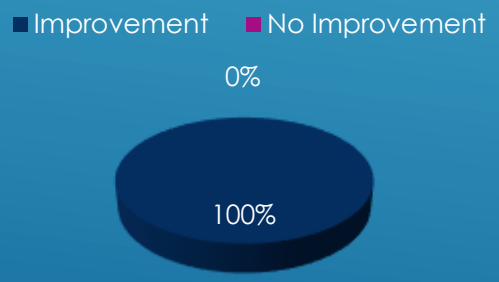

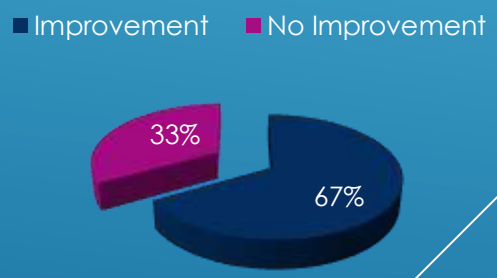

UT SOUTHWESTERN MEDICAL CENTER

OUTCOMES FOR RECONSTRUCTING THE TRIGEMINAL NERVE WITH AVANCE® NERVE GRAFT

- Safe
  - No adverse events
- Effective
  - Sensory recovery in 83% of cases
    - Similar to historic outcomes for autogenous grafts
      - Lingual nerve = 90.5% FSR or USR
      - Inferior Alveolar Nerve = 87.3%
    - Independent of age, mechanism of injury, nerve type, gap length, and Sunderland class of injury*
    - Dependent upon time to repair (chronic >90d with higher impairment score)
      - Bagheri, SC, Meyer RA, et al: Retrospective Review of Microsurgical Repair of 222 Lingual Nerve Injuries. JOMS 68:715-723, 2010, shorter interval between injury and repair better FSR and USR (*OR 0.942, p = 0.0064)
      - Bagheri, SC, Meyer RA, et al: Microsurgical Repair of the Inferior Alveolar Nerve: Success Rate and Factors that Adversely Affect Outcome. JOMS 70:1978-1990, 2012, increasing duration from injury to IAN repair results in decrease FSR (OR = 0.898, p < 0.001)
- Efficacy
  - Better than historic outcomes for entubulation = 28% to 33% with some improvement
  - Autogenous - TBD

UT SOUTHWESTERN MEDICAL CENTER

A Case Control, Multi-site, Positive Controlled, Prospective Study of the Safety and Effectiveness of Immediate Inferior Alveolar Nerve Processed Nerve Allograft Reconstruction with Ablation of the Mandible for Benign Pathology

Zuniga JR, William F, Petrisor D. JOMS 75:2669-2681, 2017doi: 10.1016/j.joms.2017.04.002

John R. Zuniga DMD, MS, PhD
The University of Texas Southwestern

John Peter Smith Hospital, Fort Worth, Texas
Fayette Williams DDS, MD

OHSC, Portland Oregon
Dan Petrisor, DDS, MD

UT SOUTHWESTERN
MEDICAL CENTER

Ablation of the mandible for benign pathology requires resection of bone, teeth, soft tissue and inferior alveolar nerve (IAN). This study was designed to determine if the immediate reconstruction of the IAN with AVANCE allograft in conjunction with the simultaneous ablation and reconstruction of the mandible will be effective in restoring sensation of the lip and chin.

Avance® Nerve Graft



Options for IAN in large continuity defects

- Autograft
- Entubulation
- Allograft

Outcomes

- Safety
- Effectiveness
- Efficacy

UT SOUTHWESTERN MEDICAL CENTER

RECONSTRUCTION: NERVE SPARING

NERVE SPARING

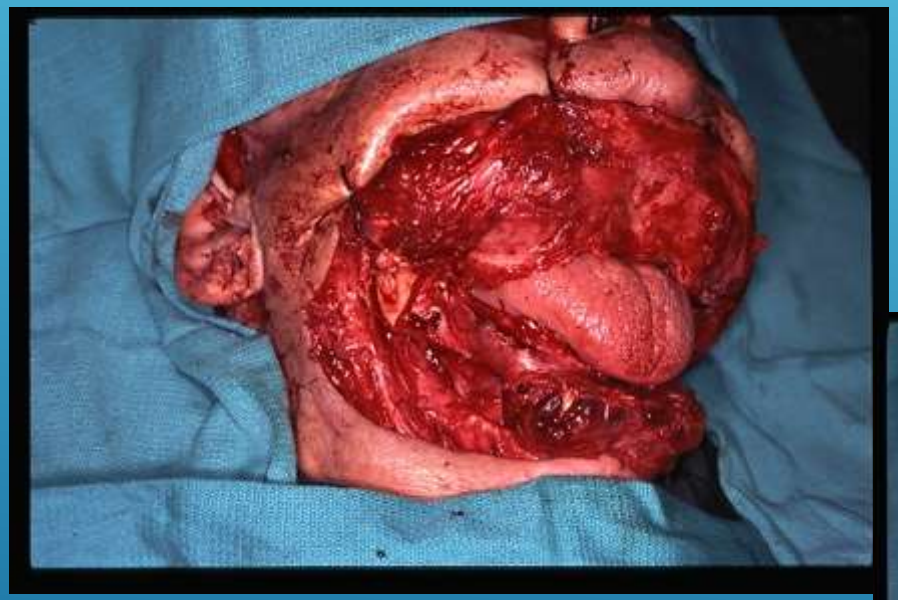

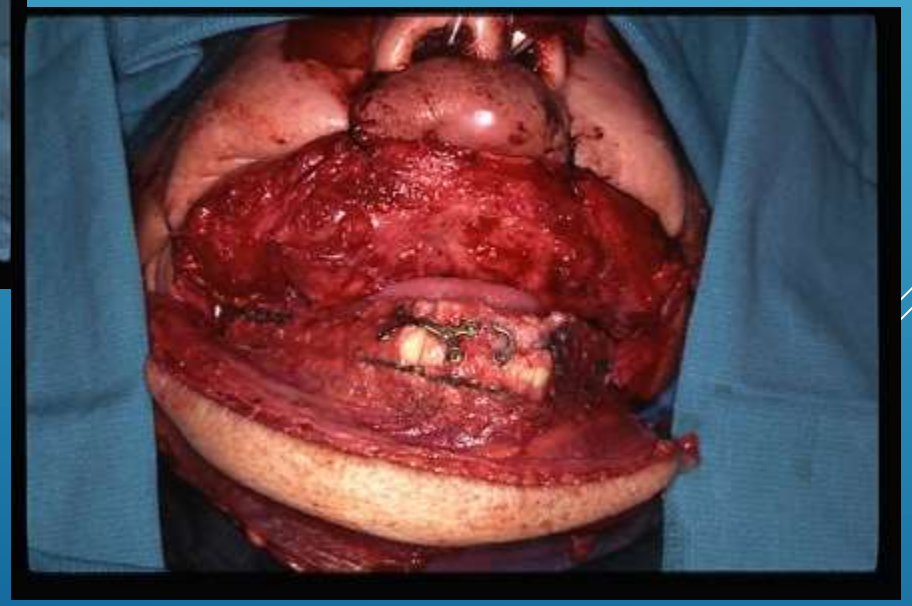

RECONSTRUCTION: AUTOGRAFTING

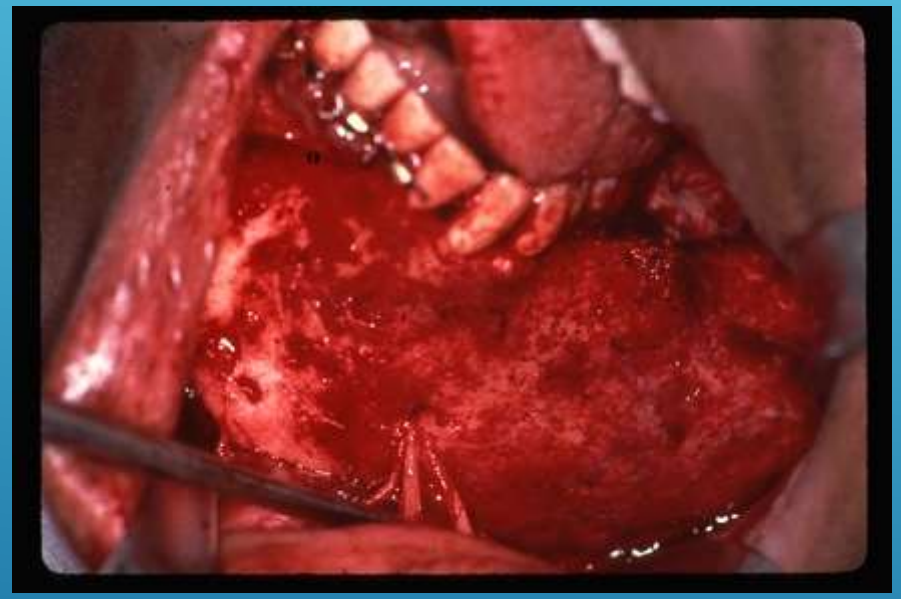

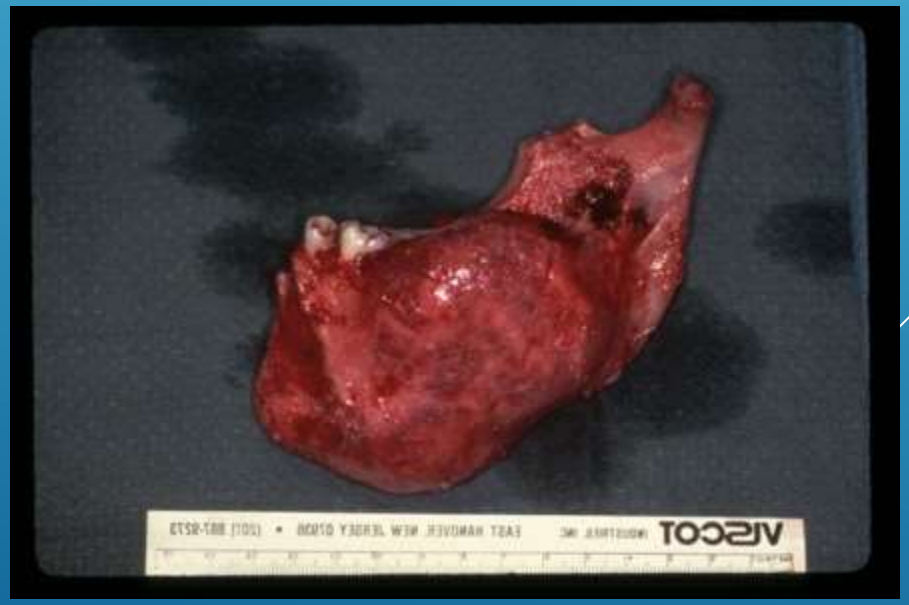

IAN AUTOGRAFTING

RECONSTRUCTION: NERVE SHARING

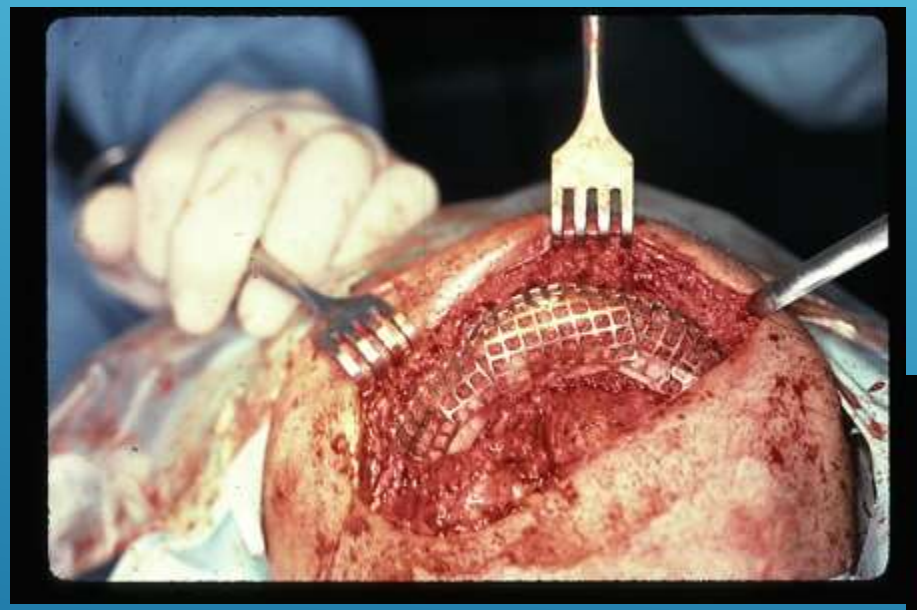

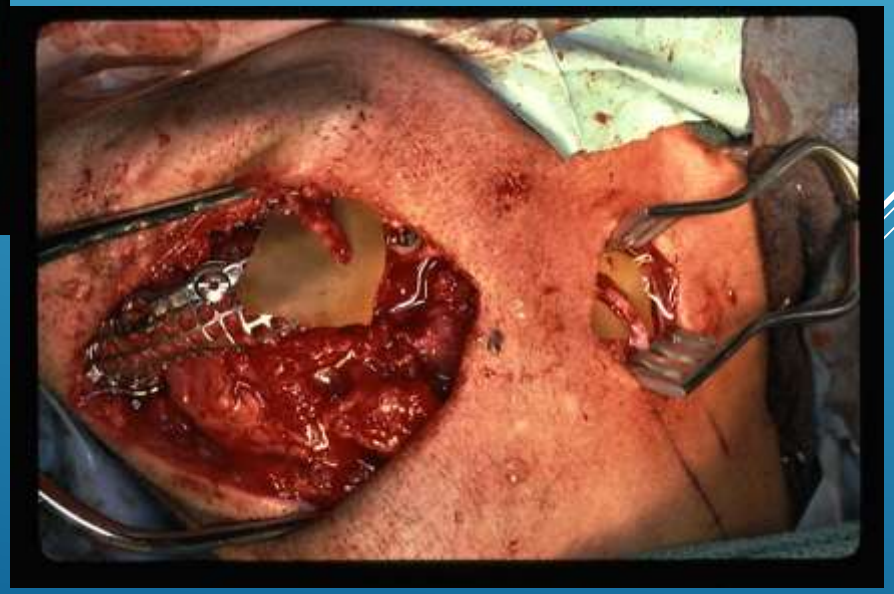

NERVE SHARING

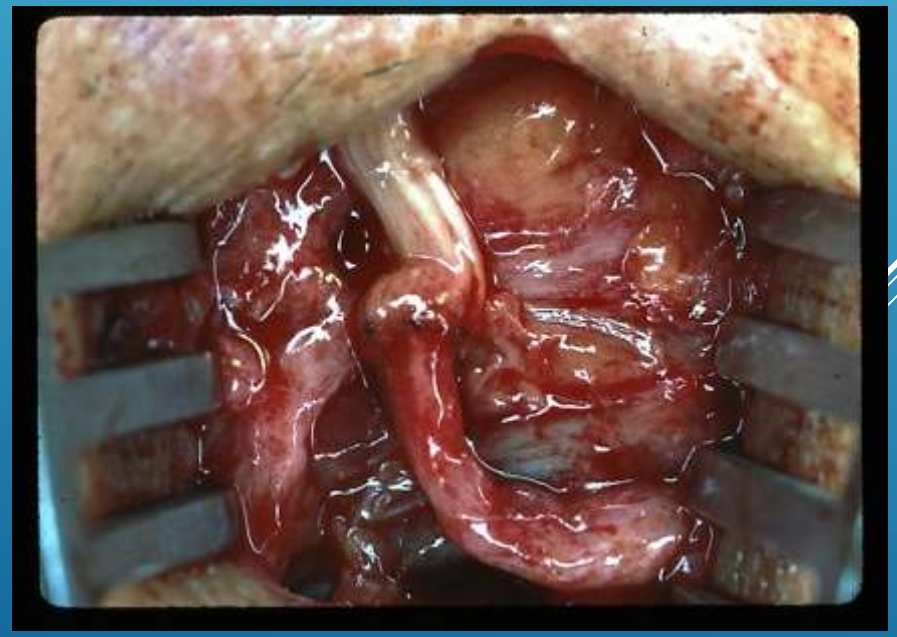

NERVE SHARING (WITH THE TRIGEMINAL NERVE)

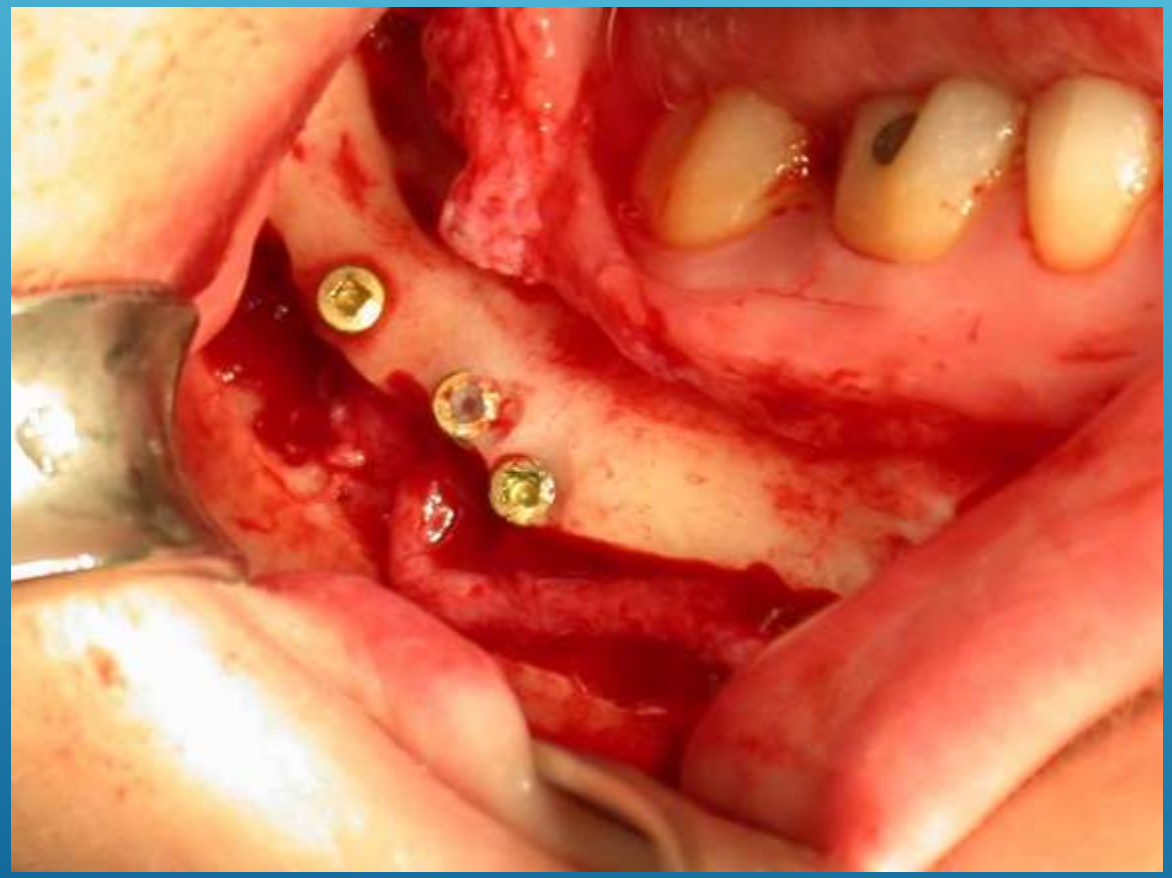

NERVE SHARING (WITH THE TRIGEMINAL NERVE)

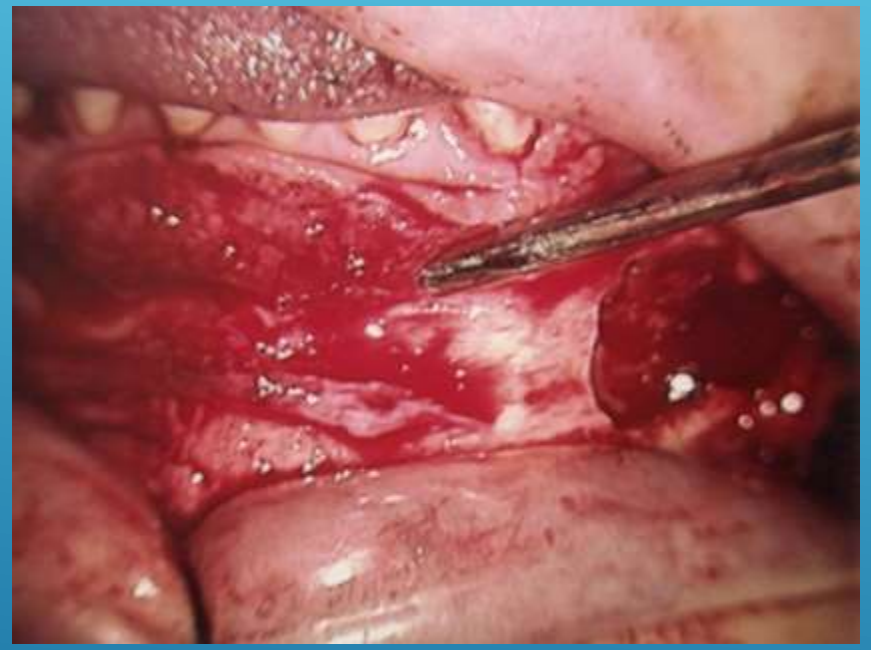

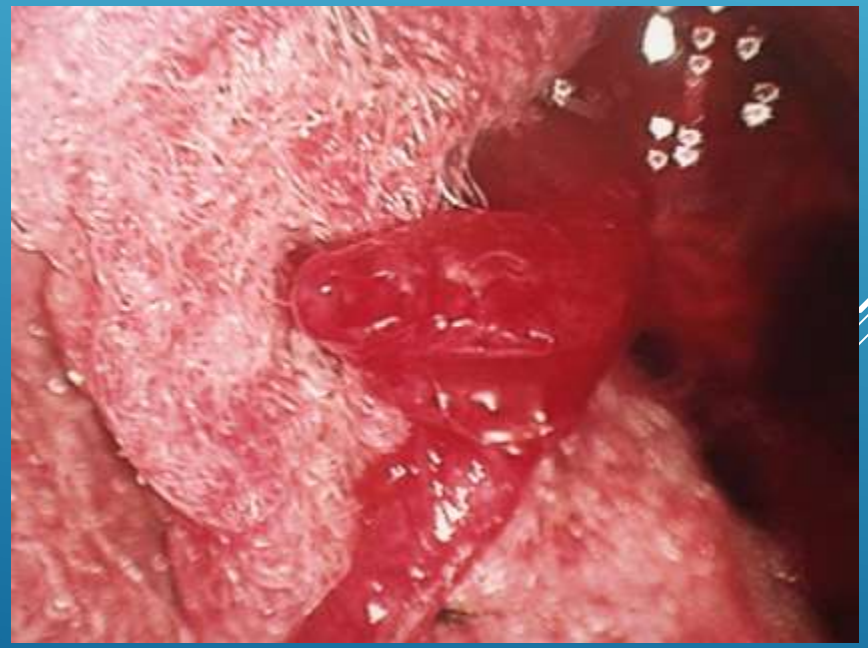

NERVE SHARING (WITH THE TRIGEMINAL NERVE)

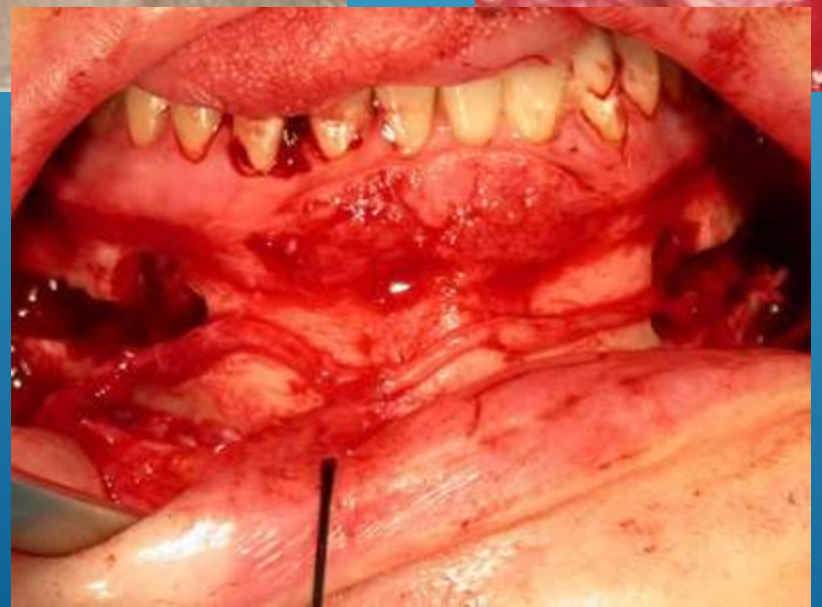


2 3 4 5 6 7 8 9


2 3 4 5 6 7 8 9 10 11

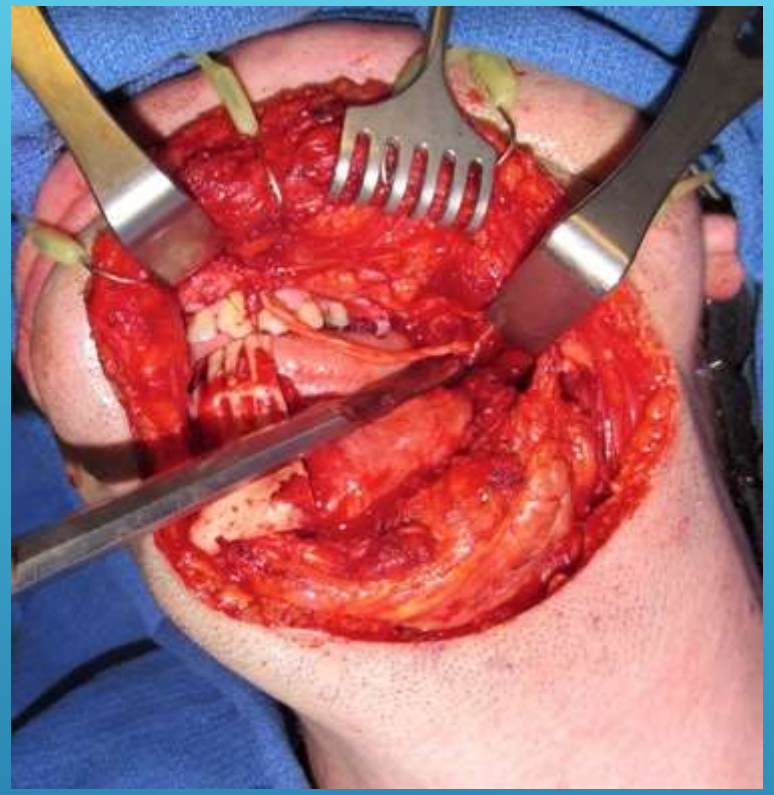

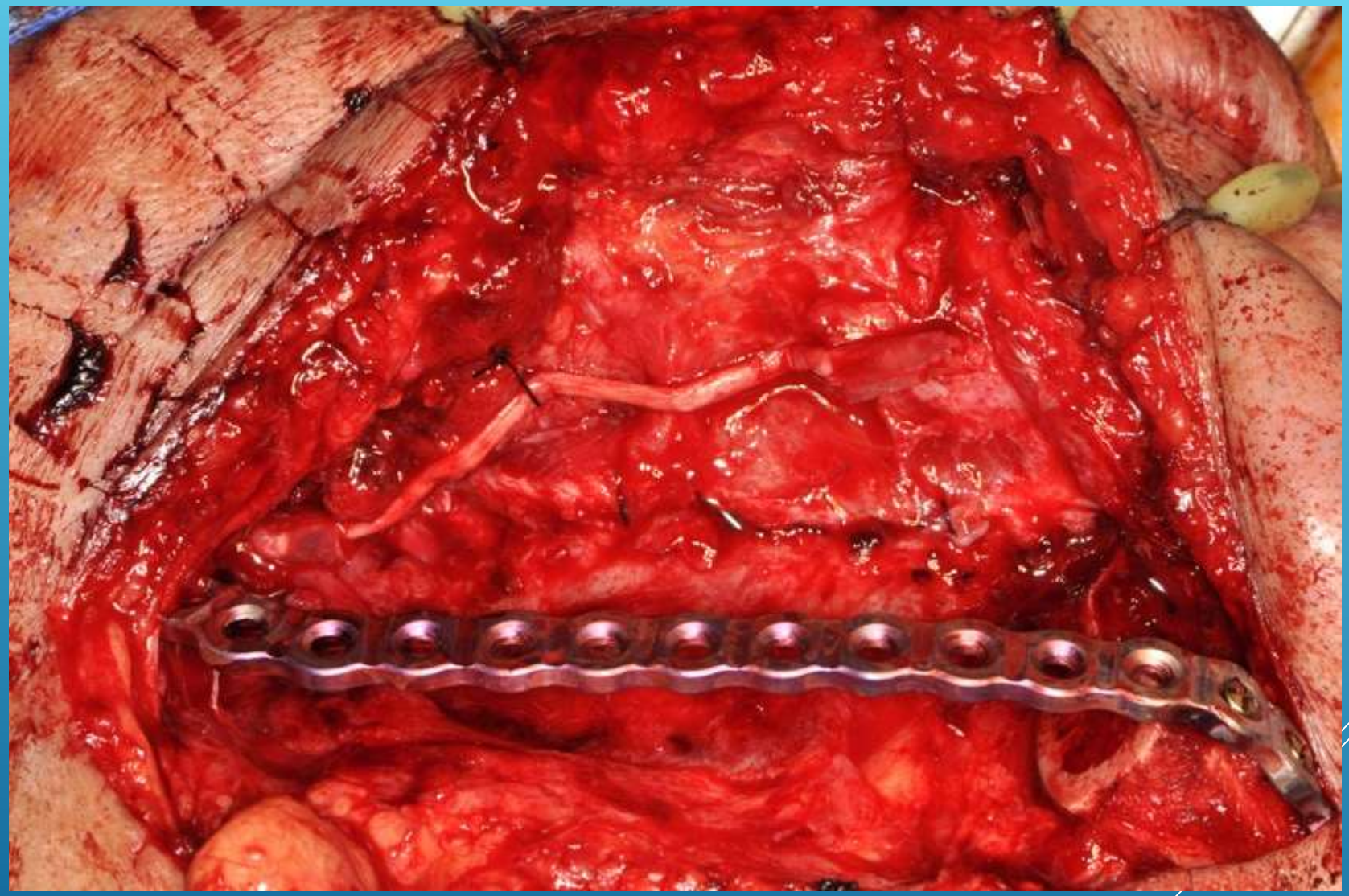

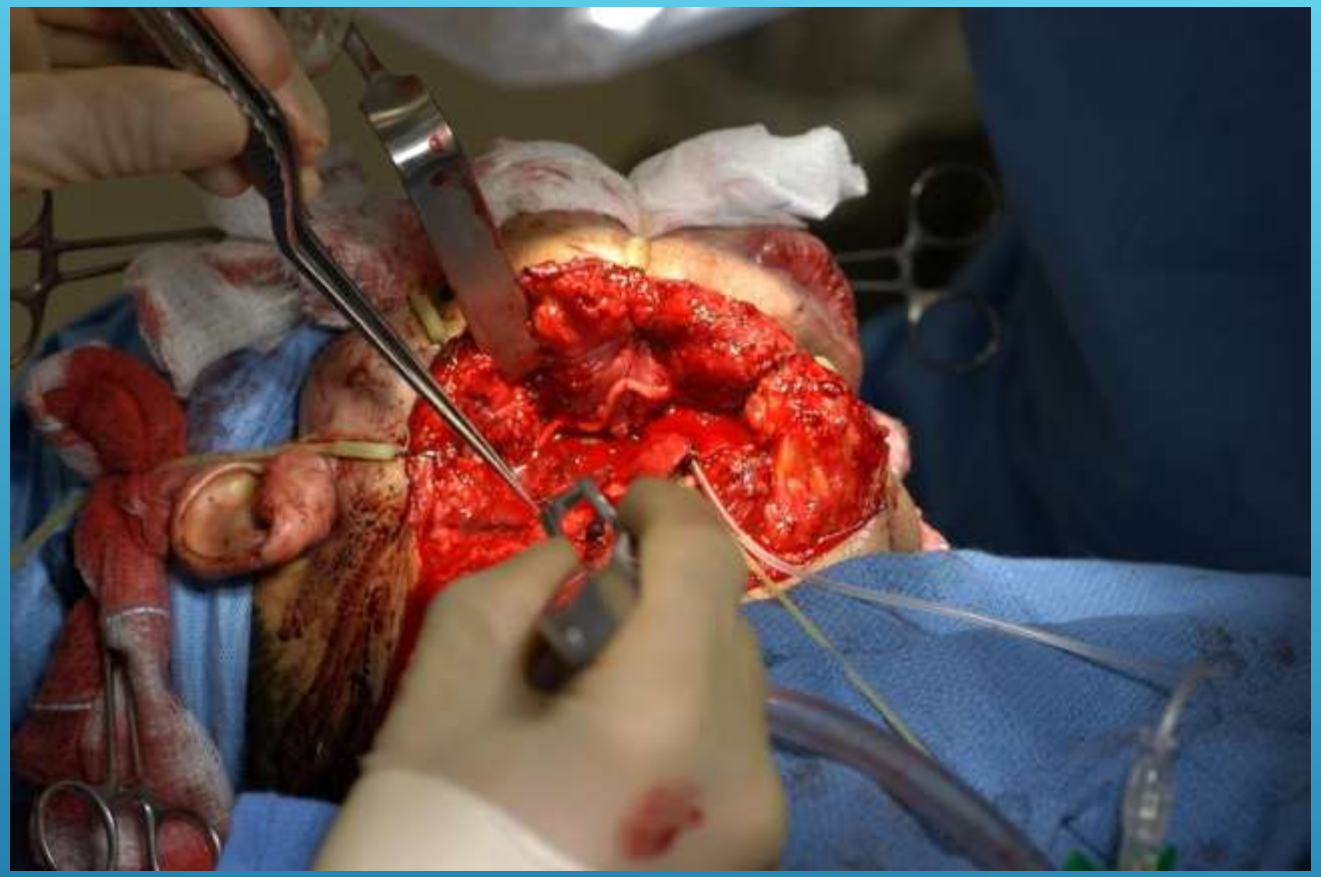

Nerve Allograft suspended to lateral flap using AXOGUARD

Bilateral IAN allograft needed

27 y/o female with large ameloblastoma

Step 1 = Intraoral surgical exposure at mental foramen

Step 2 = extraoral surgical exposure and resection

Step 3 = nerve allograft repair

Step 4 = free flap including bone and soft tissue

Exposure – step 1

Bone graft – Step 3

Resection – Step 2

Nerve graft – Step 4

IMMEDIATE NERVE ALLOGRAFT RECONSTRUCTION WITH ABLATION OF MANDIBLE FOR BENIGN PATHOLOGY

INCLUSION CRITERIA

Patients (age 5-70) requiring the ablative resection of the unilateral or bilateral mandible for benign pathology which would include the continuity injury of the IAN were included.

The length of the graft must be between 4.5 and 7.0 cm.

Sensory values recorded before and at least twice with the last recording at 12 months postoperatively.

Safety data recorded during the immediate to 12 month postoperative times.

IMMEDIATE NERVE ALLOGRAFT RECONSTRUCTION WITH ABLATION OF MANDIBLE FOR BENIGN PATHOLOGY

- **26 patients from 2010 to 2016**
- **Follow up for minimum of 6 months**
  - Useable data = 18
  - Lost to follow up or not completing 6 months = 5
  - Screen Failures
    - 3 graft not possible (2 have served as positive control)
      - 1 case – failure to identify proximal end
      - 2 cases – decision to delay mandibular reconstruction
- **Sensory Analysis**
  - **NST Sensory Score (MRSC)**
    - S0 = No sensation
    - S1 = Deep cutaneous pain (severe sensory impairment)
    - S2 = Superficial pain and touch (moderate sensory impairment)
    - S3 = Superficial pain and touch without hyperesthesia and 2PDT >15mm (mild sensory impairment) Useful sensory recovery
    - S3+ = Same as S3 with good stimulus localization and 2PDT – 7 to 15mm (normal sensory impairment) Useful sensory recovery
    - S4 = same as S3 and 2PDT = 2 to 6mm Useful sensory recovery
  - **Subjective Questionnaires**
    - **DIRECT PATH (DP)**
      - 15 questions on problems with unusual of altered feelings on face or mouth
    - **NUMERICAL RATING SCALE (NRS)**
      - 12 questions rating intensity, unpleasantness and interference with daily activities by pain or altered sensations on face
    - **WORD CHOICES (WC)**
      - 28 word list to indicate experienced any unusual or changed sensations on face in past week

UT SOUTHWESTERN MEDICAL CENTER

Mean length of discontinuity = 59.75mm (45-70)
Mean length of allograft = 62.7mm (45-70 x 2 to 4mm)

Subject #	Age	Gender	Pathology	Gap (mm)	Graft (mm)	Axoguard
101	35	Male	Ameloblastoma	70	70	2
102	11	Male	Ossifying fibroma	70	70	2
103	37	Male	Ameloblastoma	70	70	2
104	29	Male	Ameloblastoma	55	60	2
105 Screen failure (no surgery)	68	Female	OKC			
106 Screen failure (no graft placed)	26	Female	Ameloblastoma			
107	28	Female	Ameloblastoma	60	70	2
108** Screen failure (no graft placed)	23	Female	Ameloblastoma			
109	36	Female	ameloblastoma	60	65	3
110	28	Female	Ameloblastoma	50	55	3
111	22	Female	Myxoma	70	70	3
112*** Screen failure (no graft placed)	14	Female	Ameloblastoma			
113	10	Female	Ossifying fibroma	60	60	3
114	60	Female	Sclerosing osteo	50	60	3
115	12	female	Ameloblastoma	47	50	2
116	25	Male	Ossifying fibroma	45/70	50/70	3/3
117	18	Female	Ameloblastoma	45	45	4
118	14	Female	Ameloblastoma	45/45	45/45	3/3
119	18	Female	Ameloblastoma	70/70	70/70	3/3
120	64	Female	Ameloblastoma	70	70	3
121	25	Male	OKC	70	70	3
122	12	male	myxoma	60	70	3

	Study group	Screen failure group	P value
age	29.6 (10-60)	32.75 (14-68)	0.9339
gender	60% female	100% female	0.6296
pathology	60% ameloblastoma	75% ameloblastoma	0.265

UT SOUTHWESTERN MEDICAL CENTER

OVERALL NEUROSENSORY IMPAIRMENT SCORES

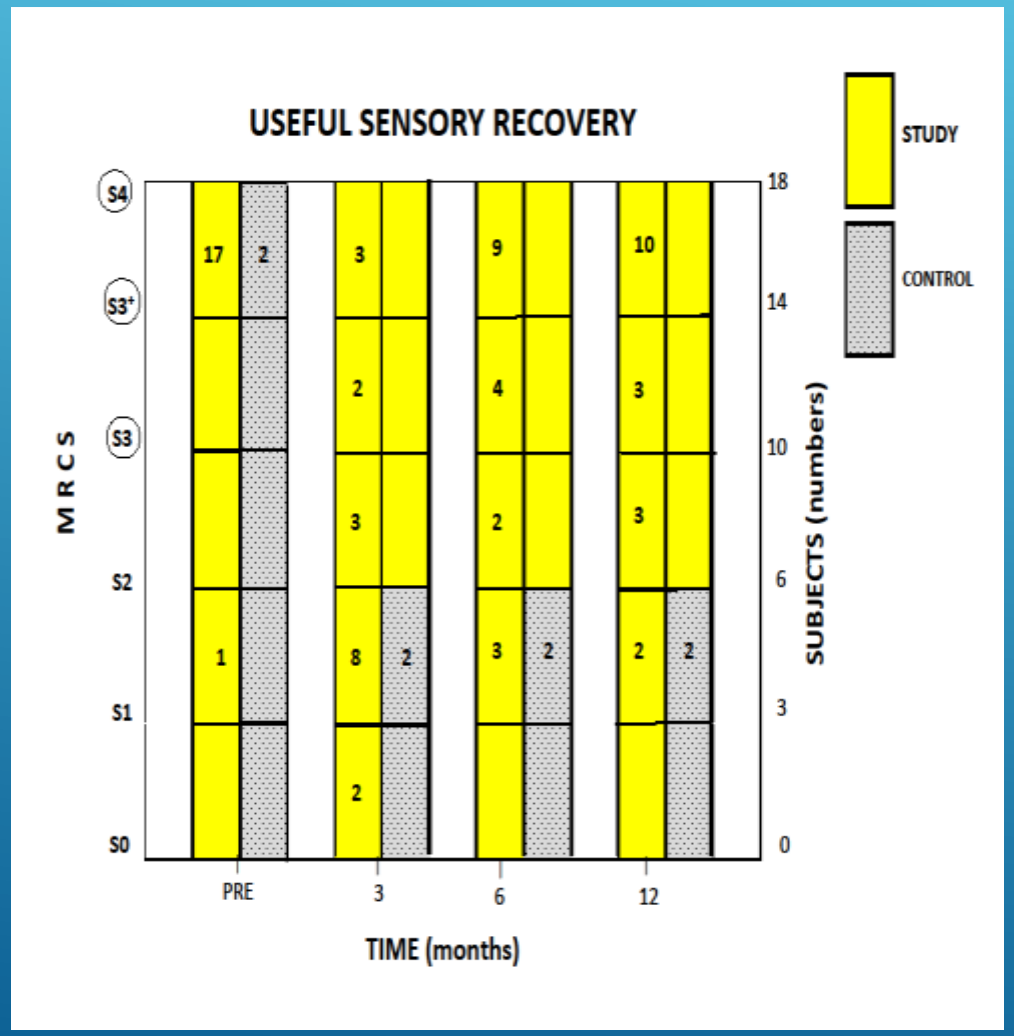

Anova= 0.003
T scores differences
a. group 1 v 2
b. group 2 v 4

8/18 USR at 3 months
15/18 USR at 6 months
16/18 USR at 12 months

UT SOUTHWESTERN MEDICAL CENTER

Attribute	N	Final NST value	P value
GAP (mm) 45-55	2	3.0 (sd – 0)	
55-65	4	3.5 (sd-0.57)	0.528
65-70	4	3.5 (sd-0.57)	
AGE <15	2	4.0 (sd – 0)	
16-30	6	3.5 (sd-0.547)	0.167
31-80	2	3.0 (sd- 0)	
GENDER Male	4	3.75 (sd-0.5)	0.792
Female	6	3.66 (sd-0.51)	

UT SOUTHWESTERN MEDICAL CENTER

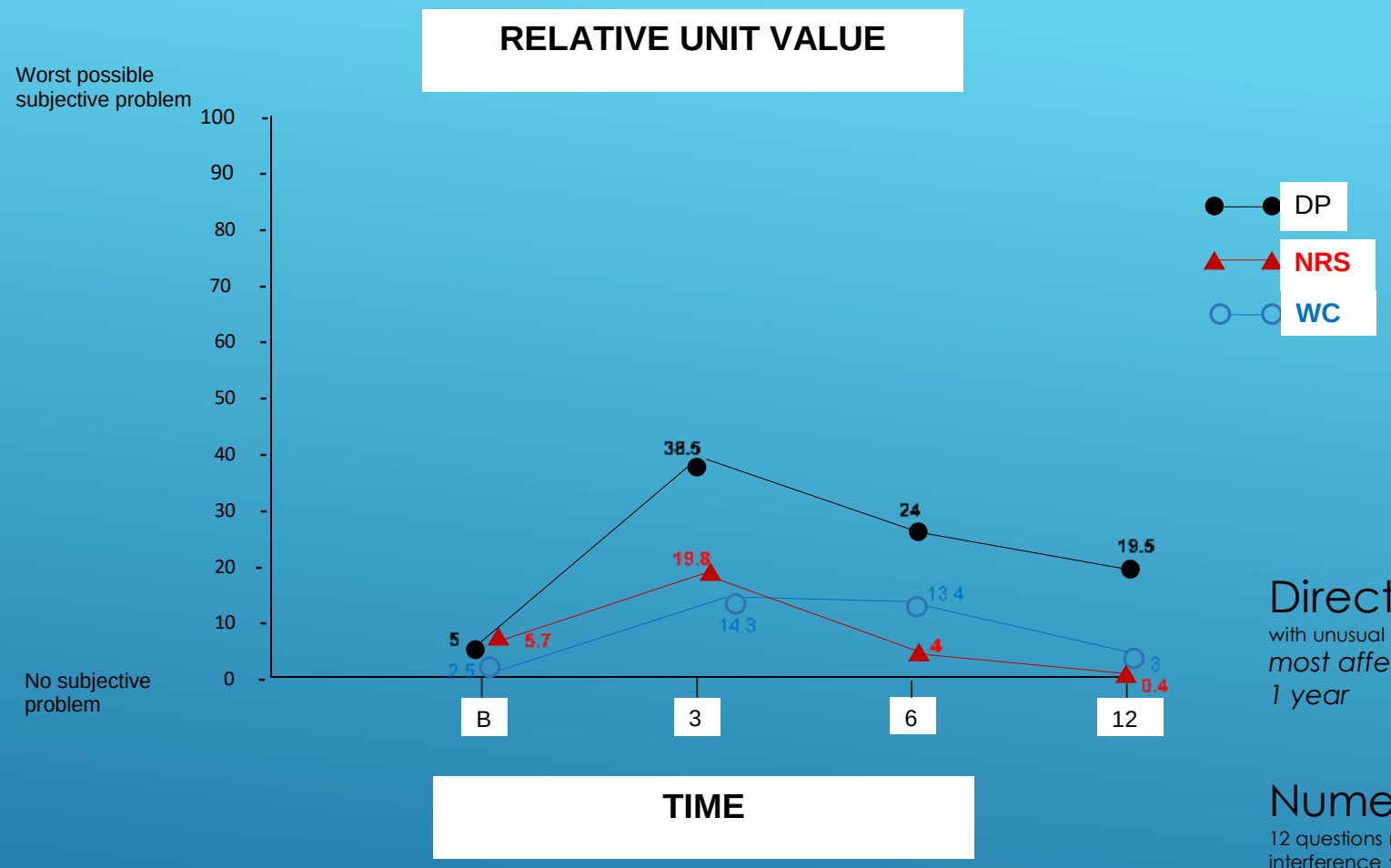

Subjective Outcome Reports by Patients

Direct Path – 15 questions on problems with unusual of altered feelings on face or mouth

most affected and less likely to resolve at 1 year

a. left over food in cheeks
b. unusual feeling in face

Numerical Rating Scale – 12 questions rating intensity, unpleasantness and interference with daily activities by pain or altered sensations on face

resolved and better than baseline at 1 year.

Word Choices - 28 word list to indicate experienced any unusual or changed sensations on face in past week

resolved and achieve baseline at 1 year

a. numbness, tingling, tickling, swelling, cool, itching most frequent at 3 and 6 months

SAFETY DATA USING IMMEDIATE NERVE ALLOGRAFT RECONSTRUCTION WITH ABLATION OF MANDIBLE FOR BENIGN PATHOLOGY

- Infections – none
- Rejections - none
- Neuropathic pain - none

UT SOUTHWESTERN MEDICAL CENTER

IMMEDIATE NERVE ALLOGRAFT RECONSTRUCTION WITH ABLATION OF MANDIBLE FOR BENIGN PATHOLOGY

CONCLUSIONS

- *Processed Nerve Allografts are safe and effective in restoring sensation to the lip and chin with 94% reaching useful and functional sensory recovery and >80% reporting similar sensations to preoperative subjective values*

UT SOUTHWESTERN MEDICAL CENTER

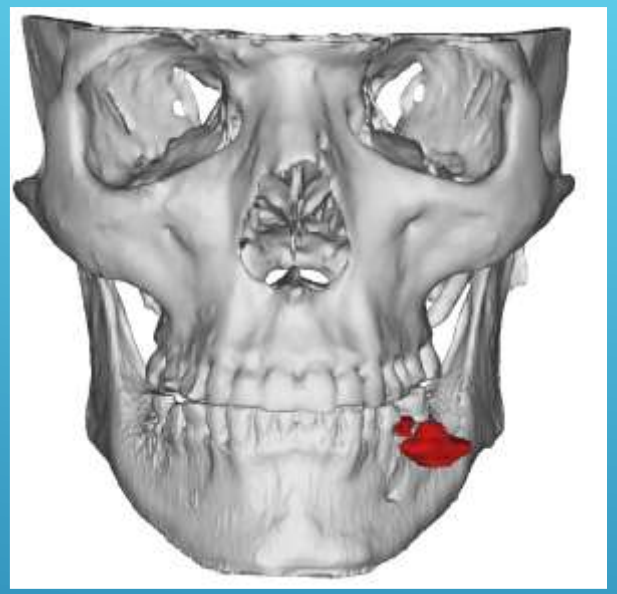

Courtesy of Dr Thomas Schlieve

54 y/o male
Ameloblastoma left mandible
No sensory deficit

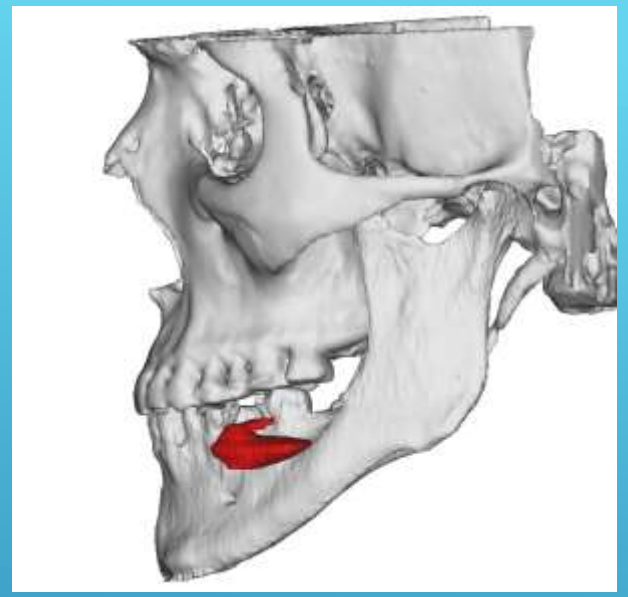

Simulated Virtual Surgical Plan

Simulated Virtual Surgical Plan

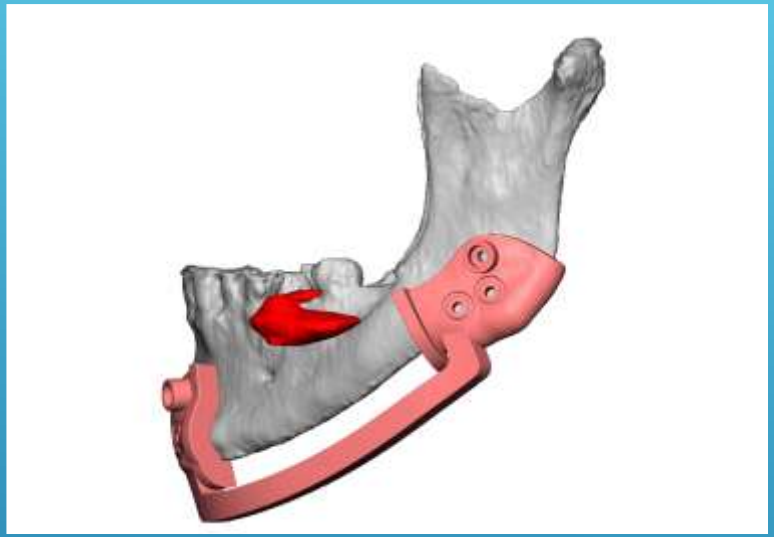

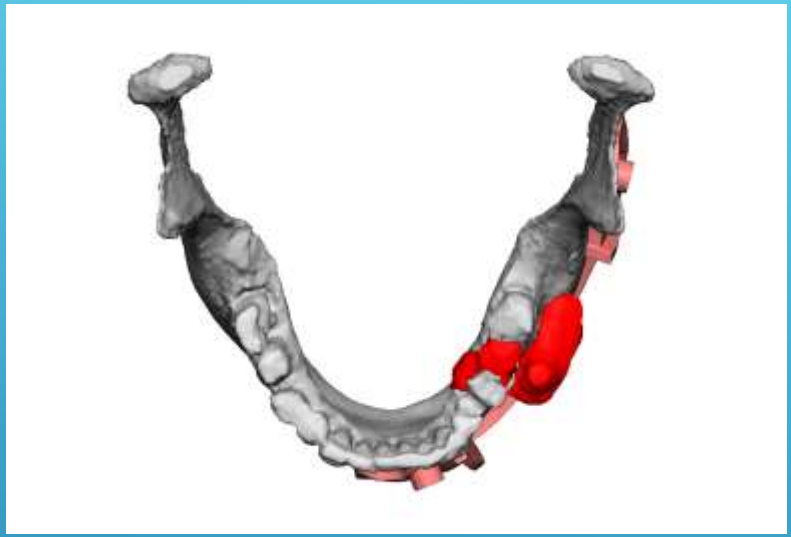

Courtesy of Dr. Thomas Schlieve

Mandible Marking Guide

Nerve Window Guide

Guide Fixation Holes

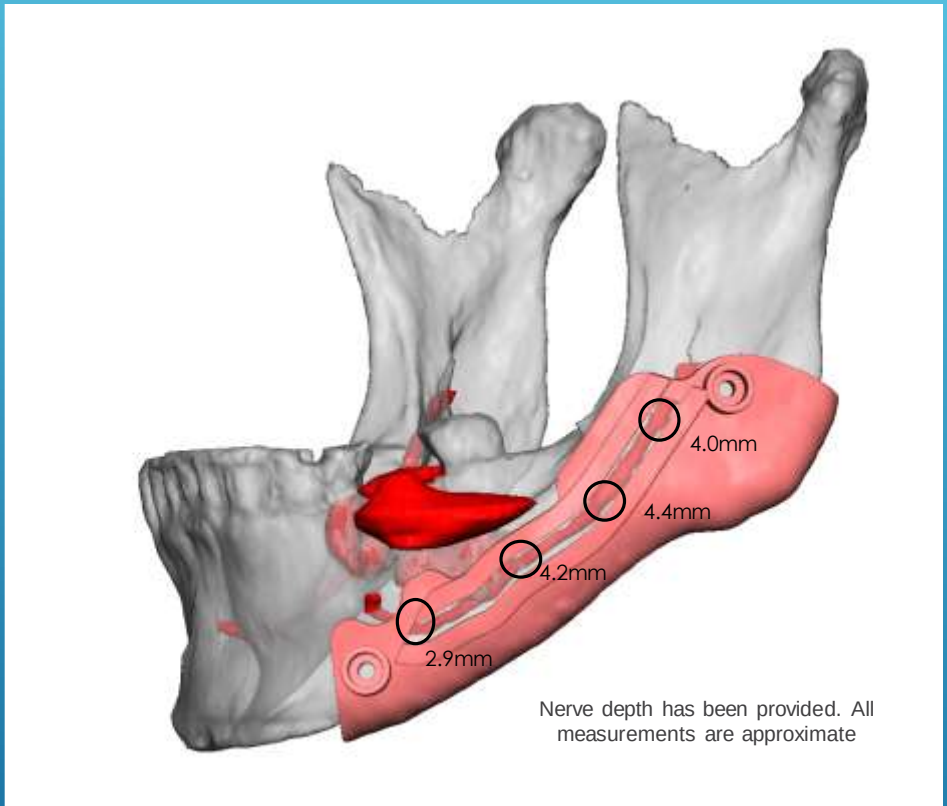

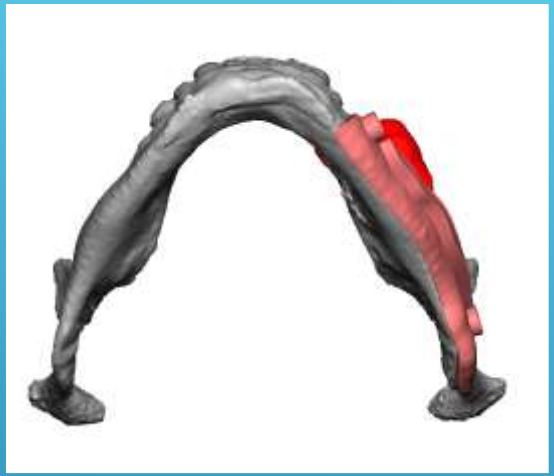

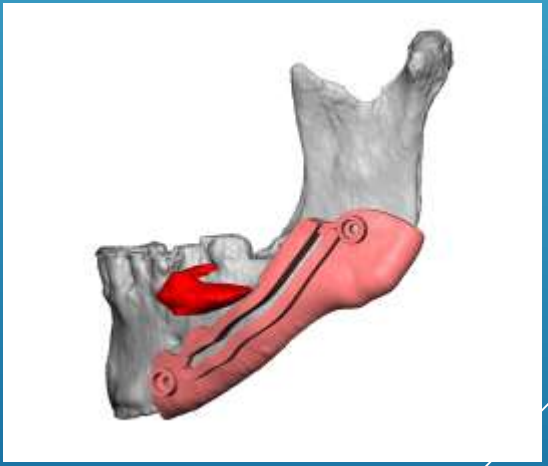

Courtesy of Dr. Thomas Schlieve

Updated design of nerve window marking guide

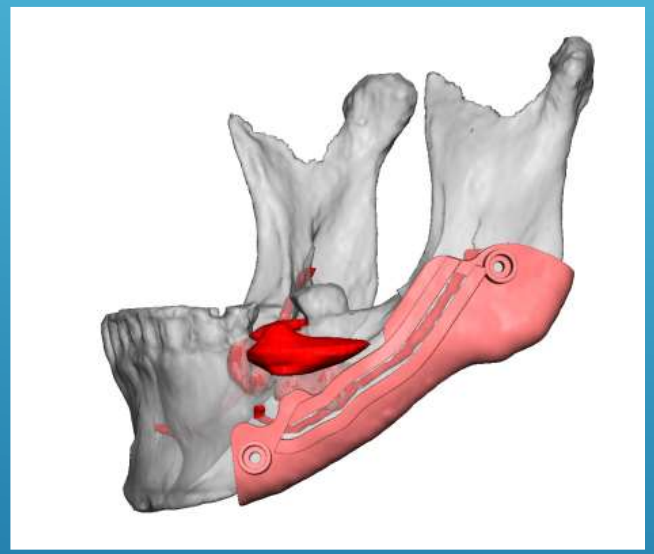

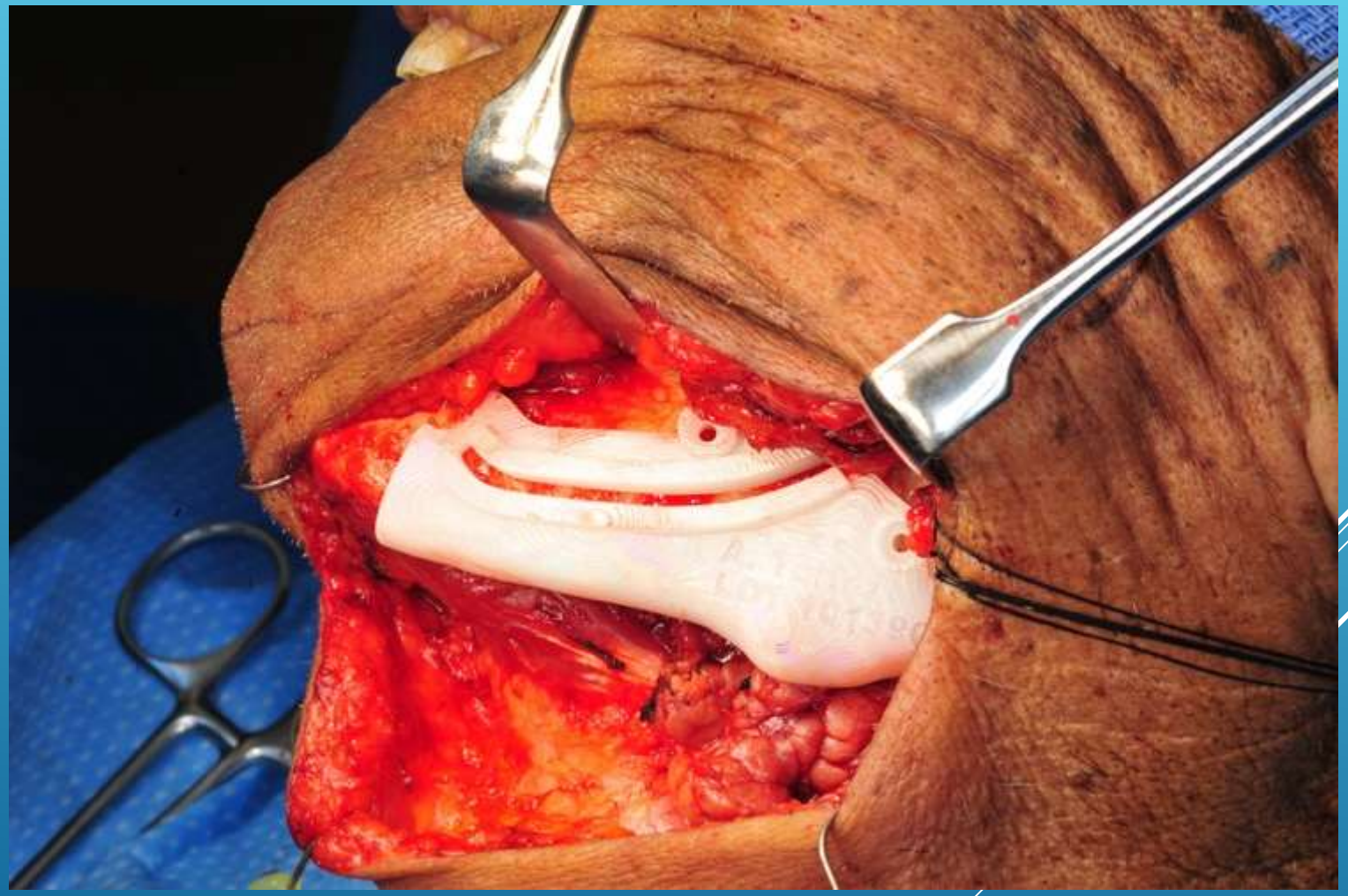

Courtesy of Dr. Thomas Schlieve

Create channel with guide and remove guide

Widen with ultrasound device and expose proximal and distal 1cm from planned resection margins

Lateralize 1cm IAN distal and proximal

Courtesy of Dr. Thomas Schlieve

Courtesy of Dr. Thomas Schlieve

Place rigid plating system temporarily and assure no impingement on IAN

Complete planned resection

AVANCE 2x3mm x 70mm

Prepare allograft for connector –assisted – repair off table for insertion

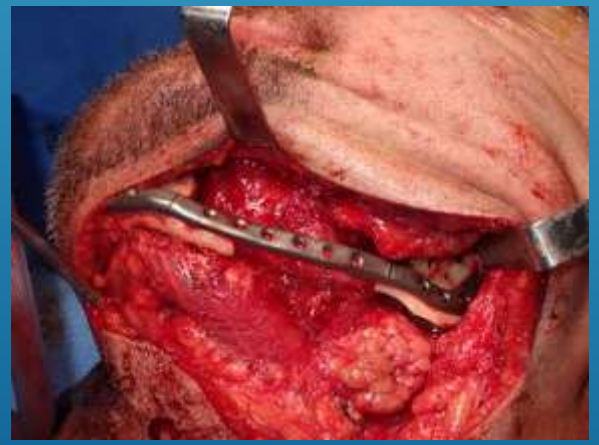

Place rigid plating system and bone graft

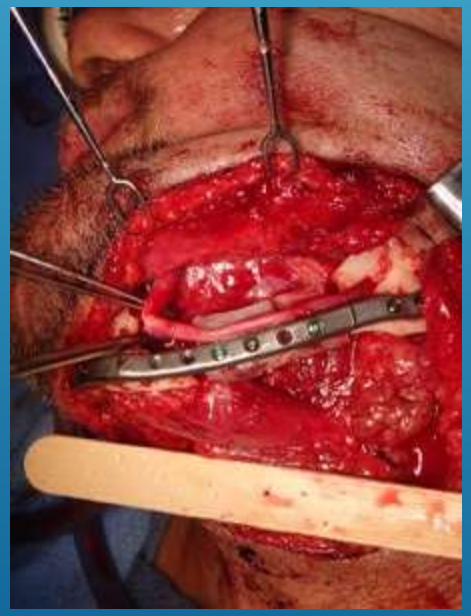

Insert nerve allograft with CAR

VSP® Reconstruction

Virtual Surgical Planning

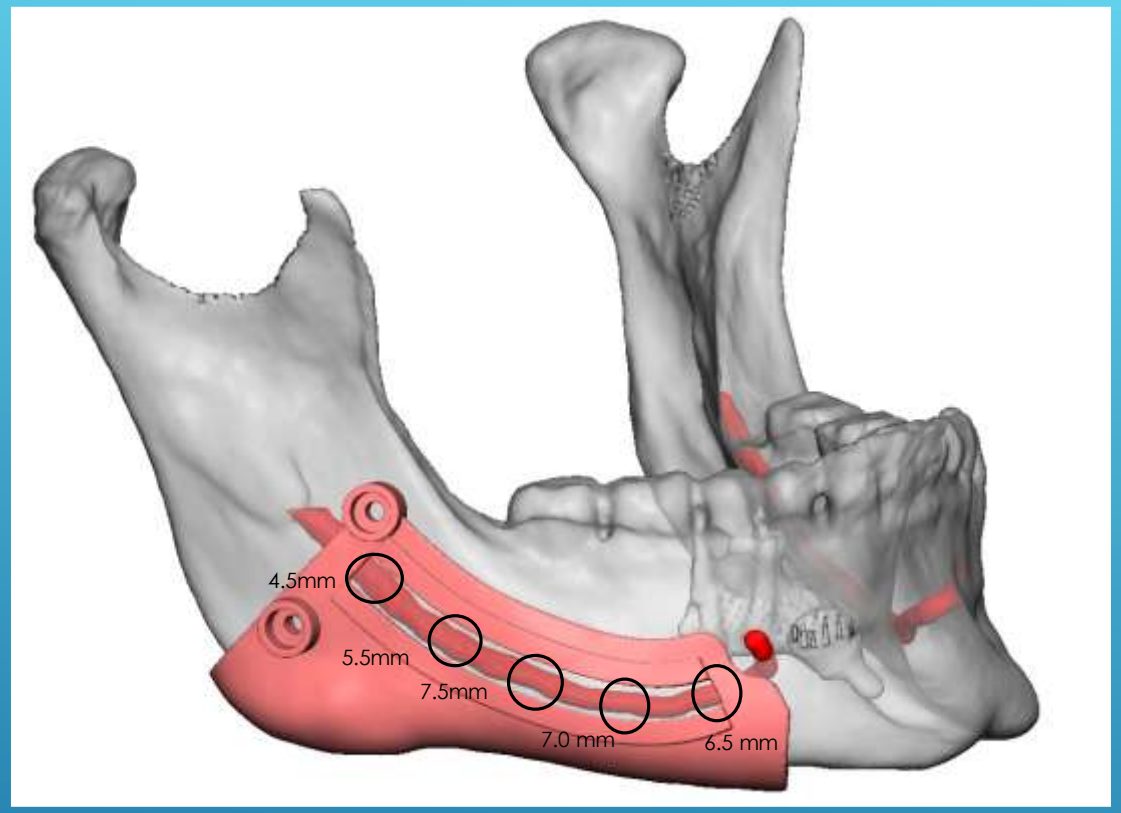

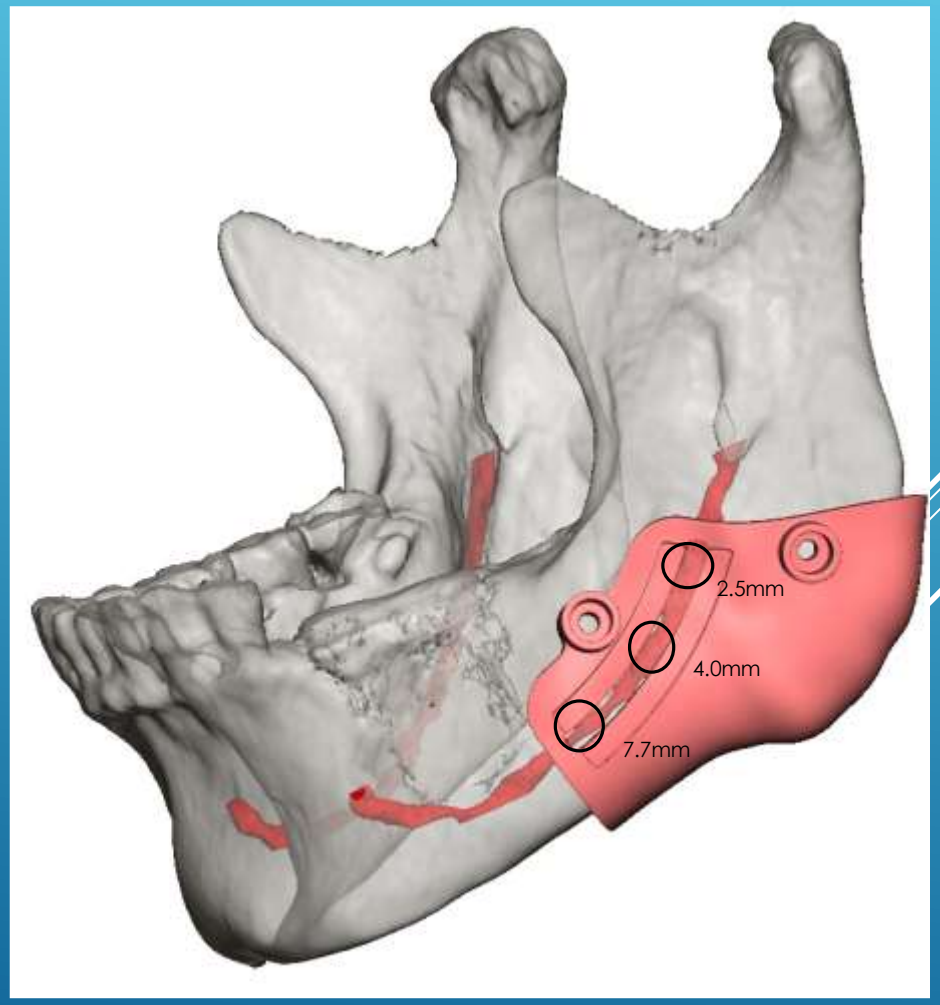

Courtesy of Dr. Thomas Schlieve

WHAT'S NEW IN MICROSURGERY FOR TRIGEMINAL NERVE REPAIR

1. Pediatric Patients
2. Malignant Disease of Mandible
3. MRONJ
4. ORN
5. BMP

1. 3-D Microscopy
   Orb Eye

2. Navigational and Point Specific
   Synaptive

93351735
DOS = 6/1/18

Proximal and Distal right lingual nerve isolation

Large amputation neuroma proximal end = Class V

93629145
DOS= 8/31/2018

ORBEYE USED
TECHNIQUE DEMONSTRATIONS WITH SONOPET

Sonopet used for ostectomy to IAN

93629145
DOS= 8/31/2018
ORBEYE USED

Uncovering IAN with sonopet

Class V injury right inferior alveolar nerve after exposure

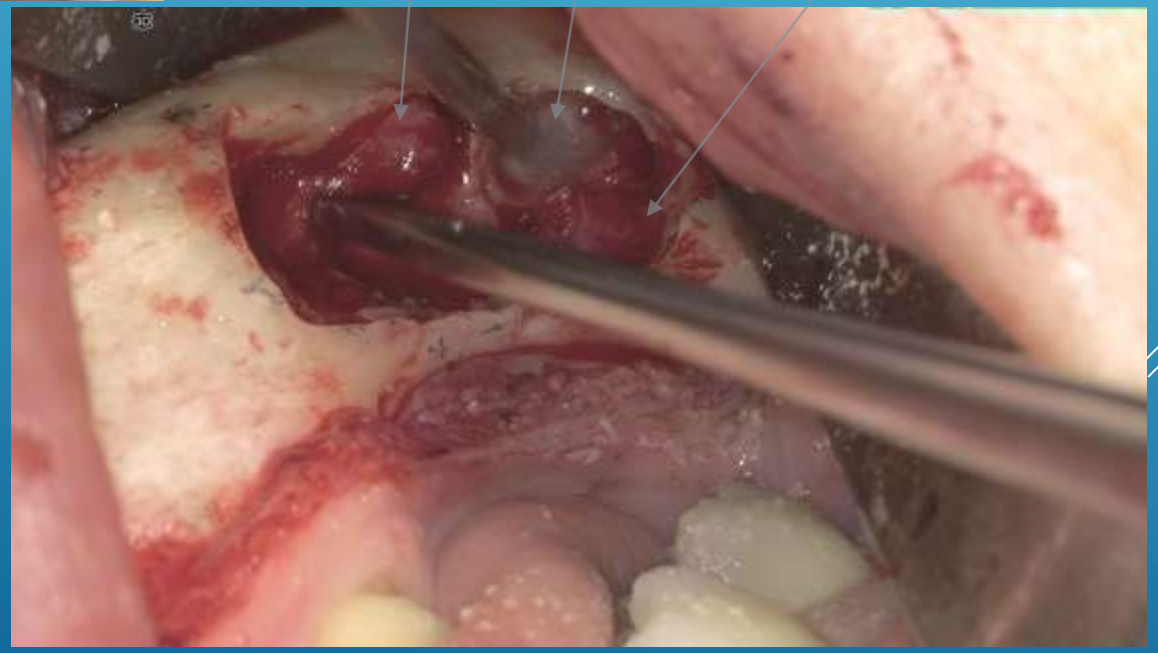

93629807
DOS = 8/31/2018

ORBEYE USED

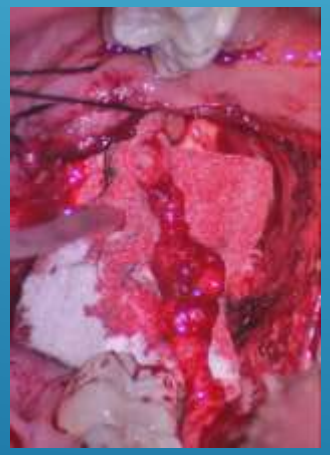

Right lingual nerve

Neuroma – in - continuity

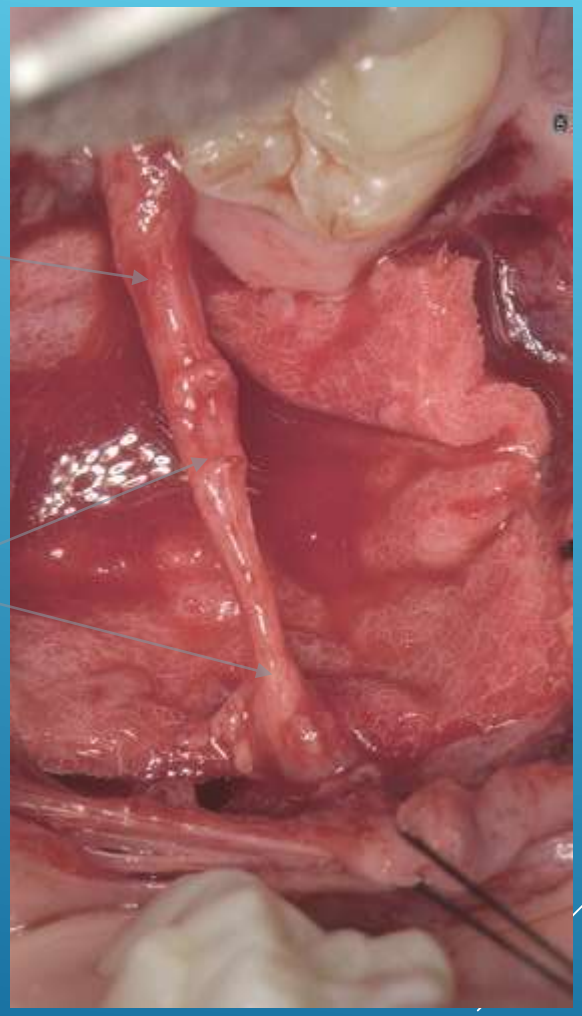

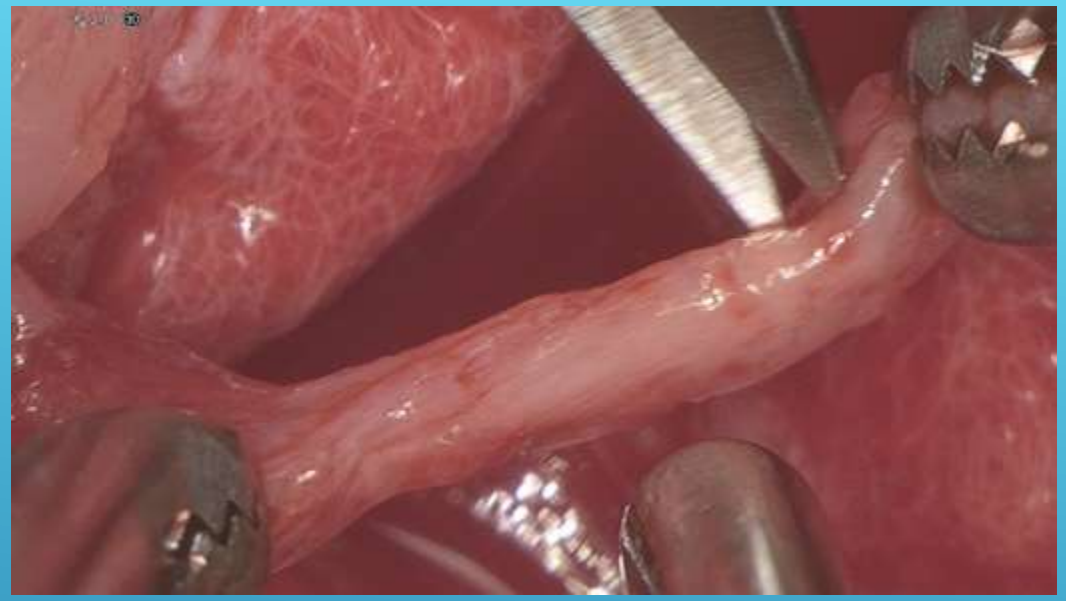

High magnification of Neuroma- in - continuity

12mm gap

93629807
DOS = 8/31/2018
orbeye used

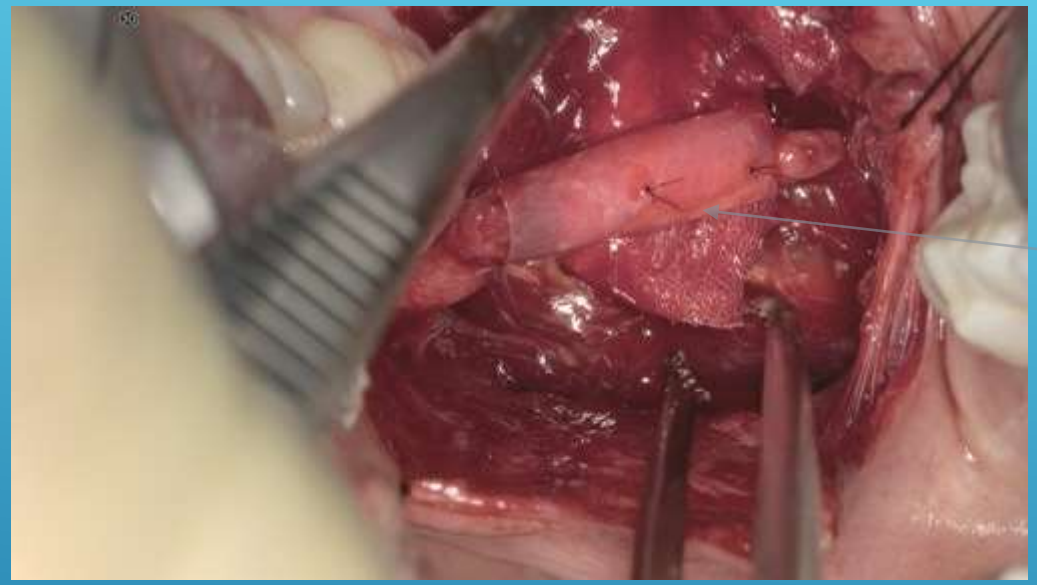

93629807
DOS = 8/31/2018
orbeye used

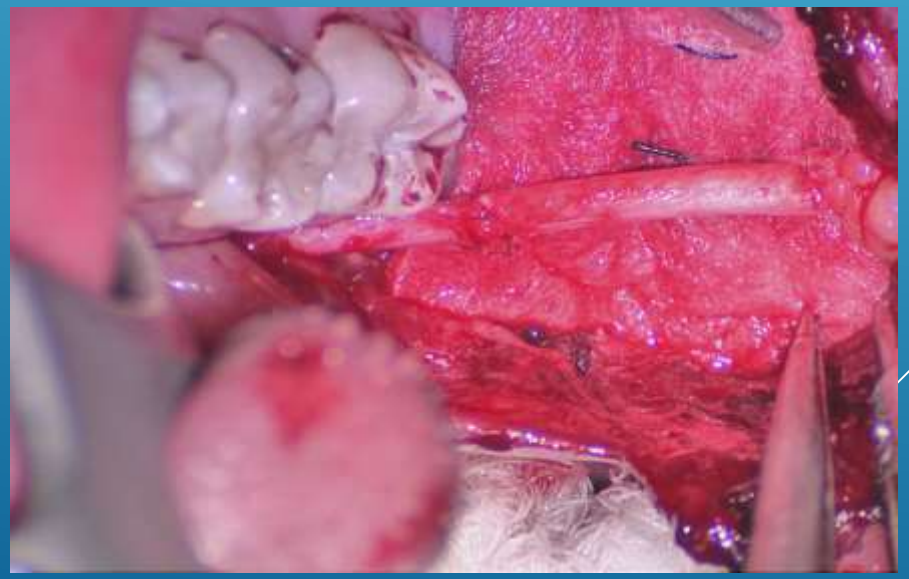

BREAK TIME!!

FLORIDA SOCIETY OF ORAL AND MAXILLOFACIAL SURGEONS

MR DETECTION IN THE DIAGNOSIS AND MANAGEMENT OF TRAUMATIC AND PLANNED TRIGEMINAL NERVE INJURIES

John R. Zuniga DMD, MS, PhD
Robert V. Walker DDS Chair in Oral and Maxillofacial Surgery
Professor, Departments of Surgery and Neurology & Neurotherapeutics
University of Texas Southwestern
Parkland Hospital
Children's Medical Center
Dallas, Texas

FSOMS Mission

The mission of the Florida Society of Oral & Maxillofacial Surgeons is to improve the health of Florida residents through high practice standards, public and professional advocacy, ethical behavior, and to support its members through continuous professional education and advancement of the specialty.

Established 1960

FSOMS

Misadventures in third molar surgery

Pre-Op

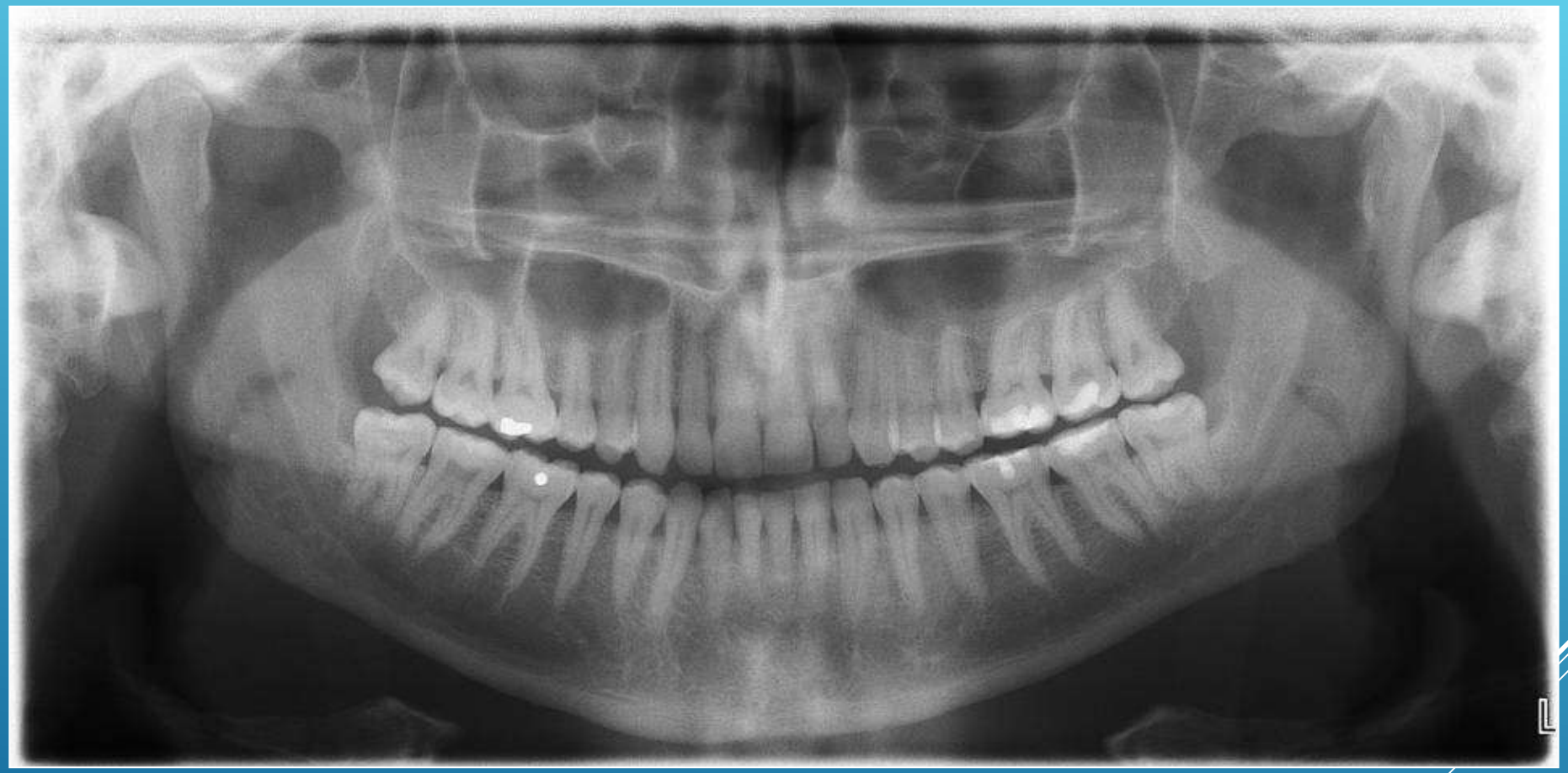

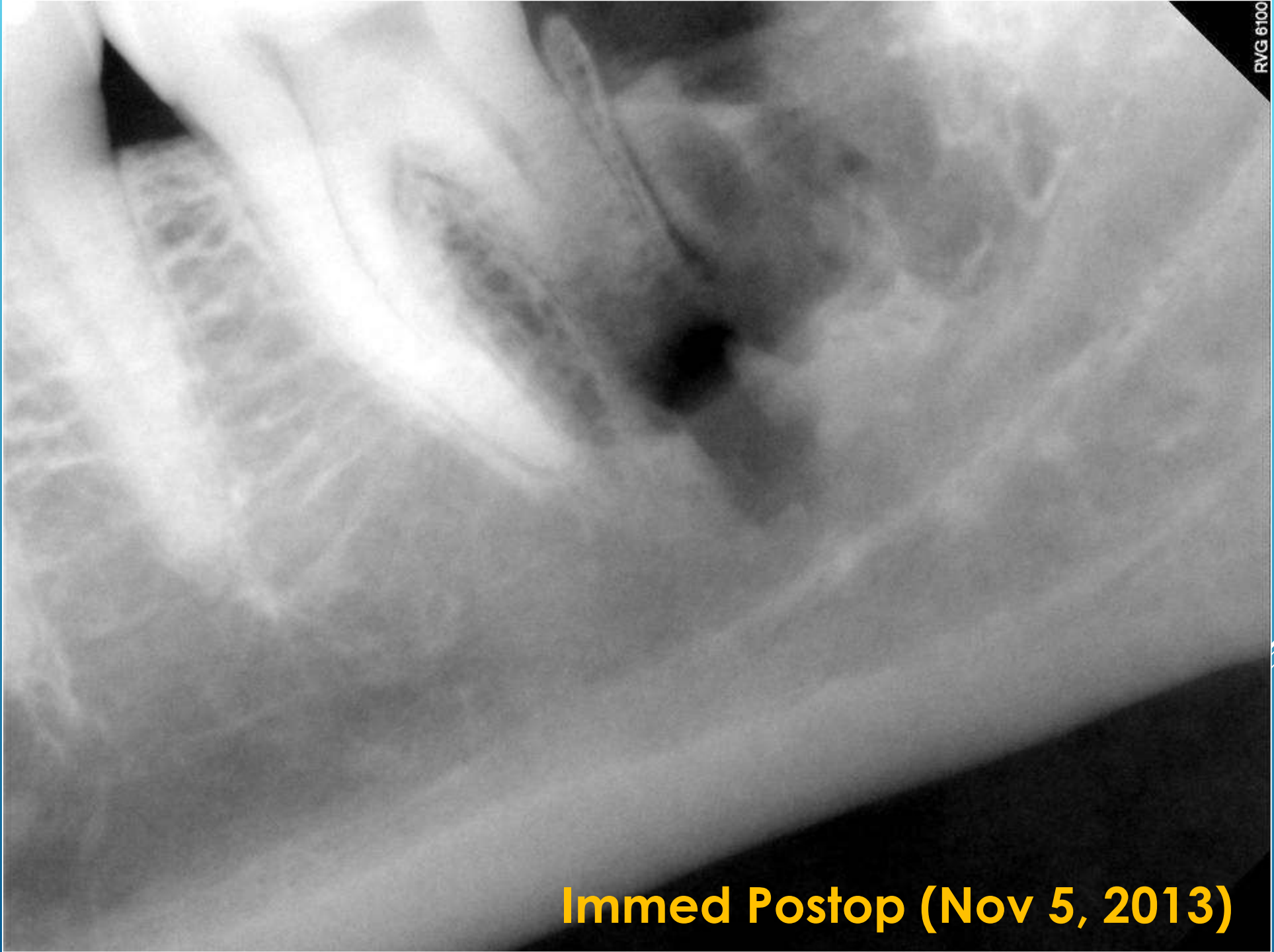

Immed Postop (Nov 5, 2013)

1 wk (Nov 11, 2013

Misadventures in implant surgery

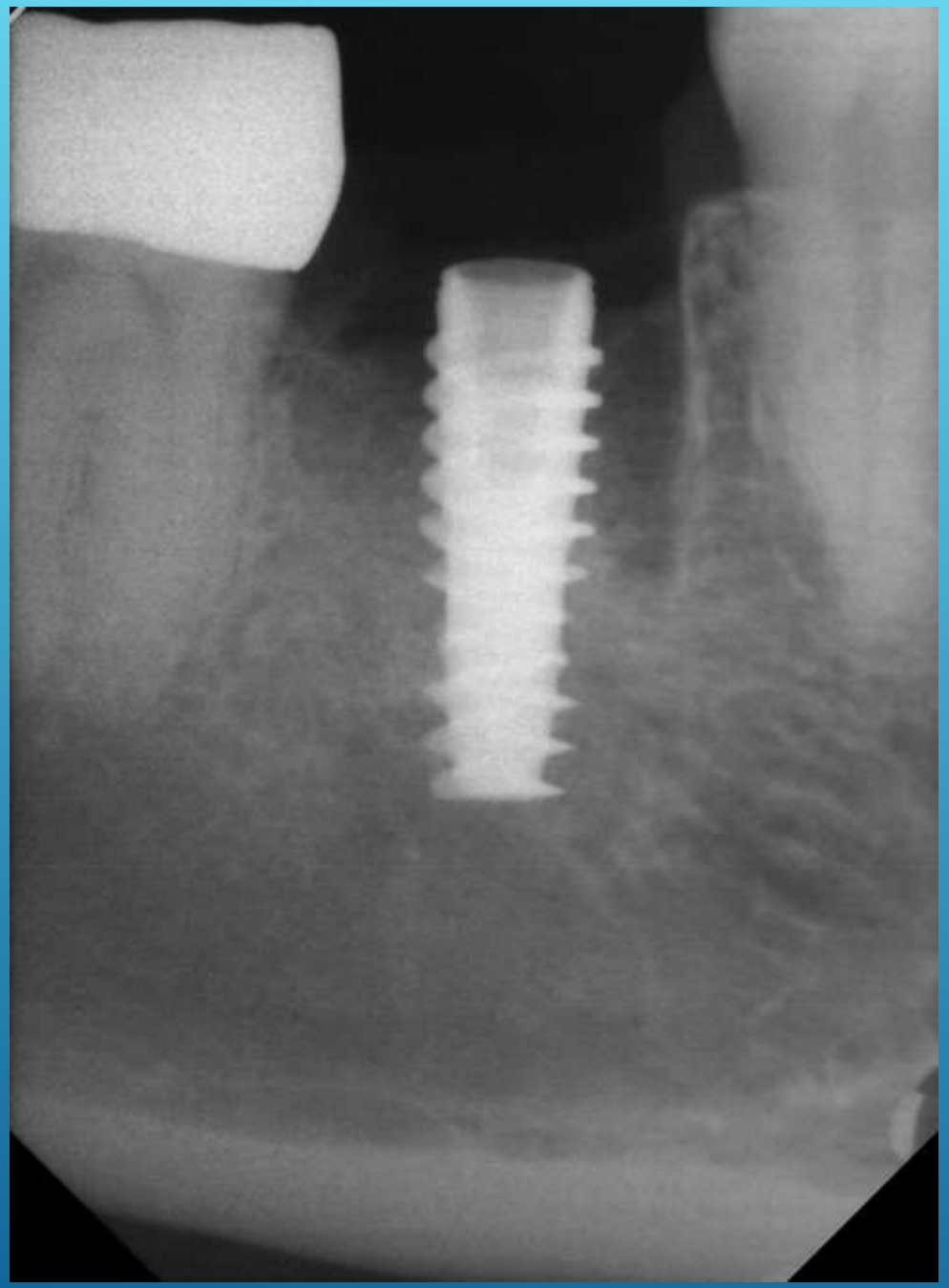

8158 Closed Claims Through 2008

Nerve damage cases

Dental alveolar	704
Implants	114
Orthognathic	79
TMJ	30
Trauma	10
Cosmetic	1
Total	938

- Incidence of Nerve Injury Consultation (by frequency)
  - IAN (64%)
  - LN (30%)
  - Other (less significant)
- Degree of Nerve Injury (by severity)
  - LN
  - IAN
  - Other (less significant
- Etiology (by decreasing frequency)
  - Odontectomy
  - Orthognathic surgery
  - Local anesthetic injection
  - Implant surgery

Nerve damage cases

Dental alveolar	704
Implants	114
Orthognathic	79
TMJ	30
Trauma	10
Cosmetic	1
Total	938



Odontectomy

Most common procedure which led to referral
Severe Impairment
- 50% of LN
- 25% of IAN

Nerve Surgery was offered
- 87% LN
- 36% IAN

Implant Surgery

Exclusively causes injury to only the IAN
More common in females (6:1)
Patients are generally much older (56 y/o)
Impairment scores are less severe than odontecomy and orthognathic injuries to IAN
- No sensory impairment to moderate sensory impairment

Clinical Characteristics of Trigeminal Nerve (TN) Injury Referrals to a University Centre

A. Tay, J. Zuniga, Int J Oral Maxillofac Surg 36>922-927, 2007

Diagnosis

TRIGEMINAL NERVE INJURY ALGORITHM

IN DECISION MAKING IN ORAL AND MAXILLOFACIAL SURGERY, *EDS. LASKIN & ABUBACKER,* 2007

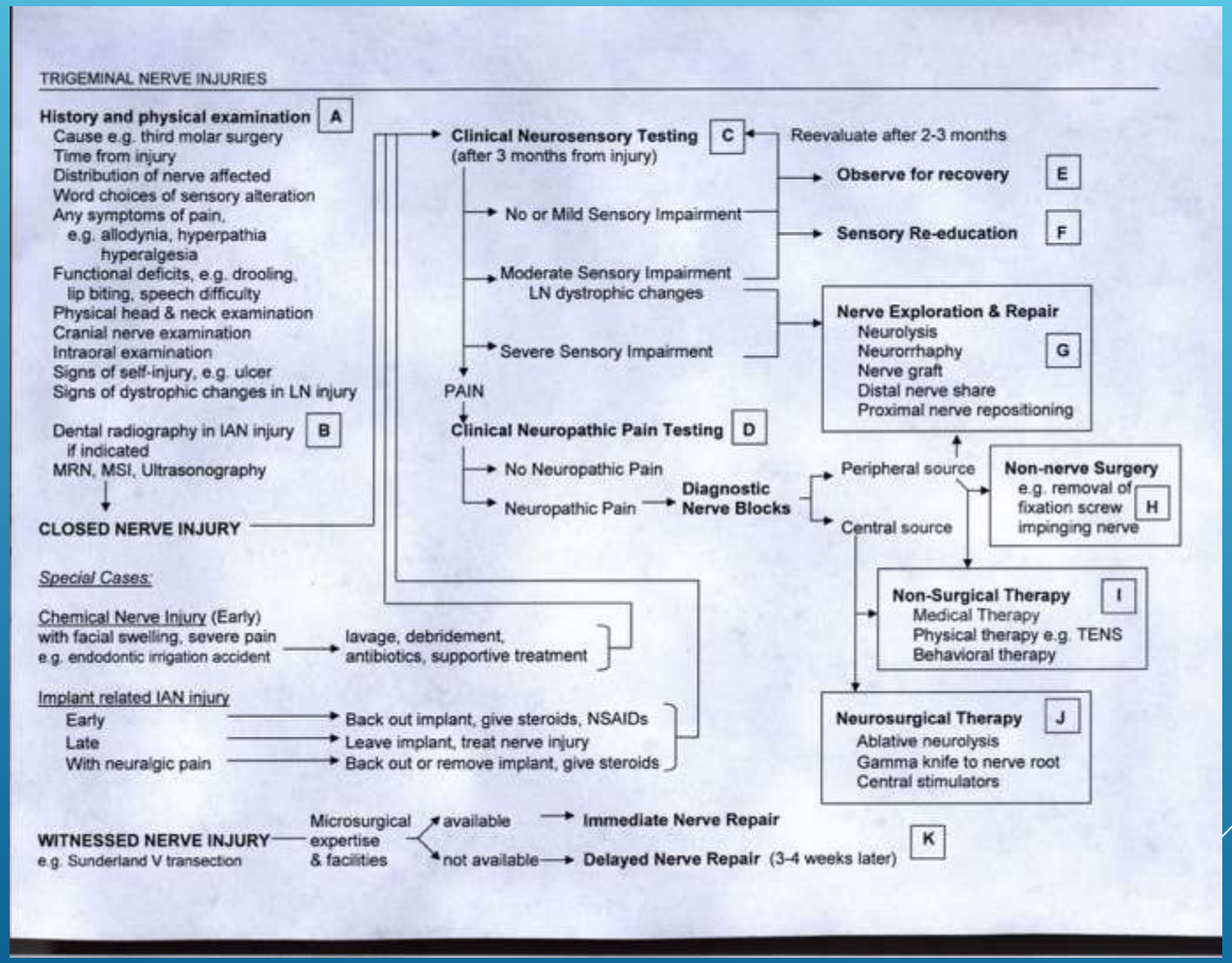

OMFS Clin North Amer 4: 353-367, 1992

A Contemporary Approach to the Clinical Evaluation of Trigeminal Nerve Injuries

John R. Zuniga DMD, MS, PhD, Greg K. Essig DDS, PhD

J Oral Maxillofac Surg 552-8 1998

The Accuracy of Clinical Neurosensory Testing for Nerve Injury Diagnosis

John R. Zuniga, DMD, PHD, MS, Roger A. Meyer, DDS, MD, John M. Gregg, DDS, PHD, MS, Michael Miloro, DMD, MD, and, Leon Davis DDS, MS, MD

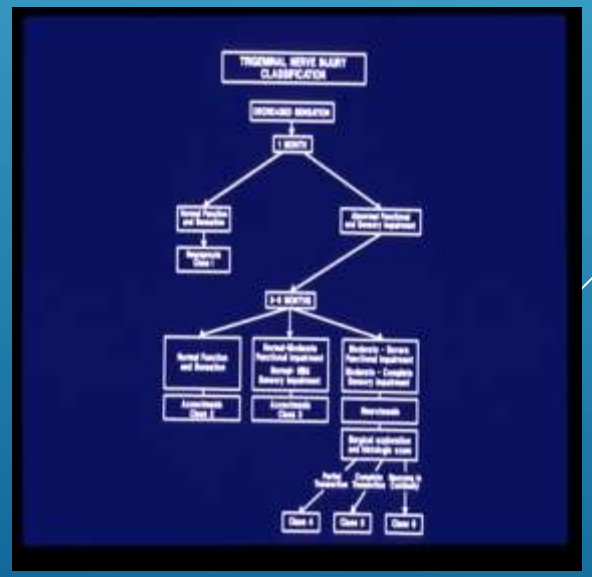

A. HISTORY AND PHYSICAL EXAMINATION

- Causes
  - Third molar
  - implant
- Time from injury
- Distribution
- Word choices
  - Normal
  - Paresthesia
  - dysesthesia
- Pain
  - Stimulus induced
  - spontaneous
- Functional deficits
  - Lip biting
  - Speech
  - taste



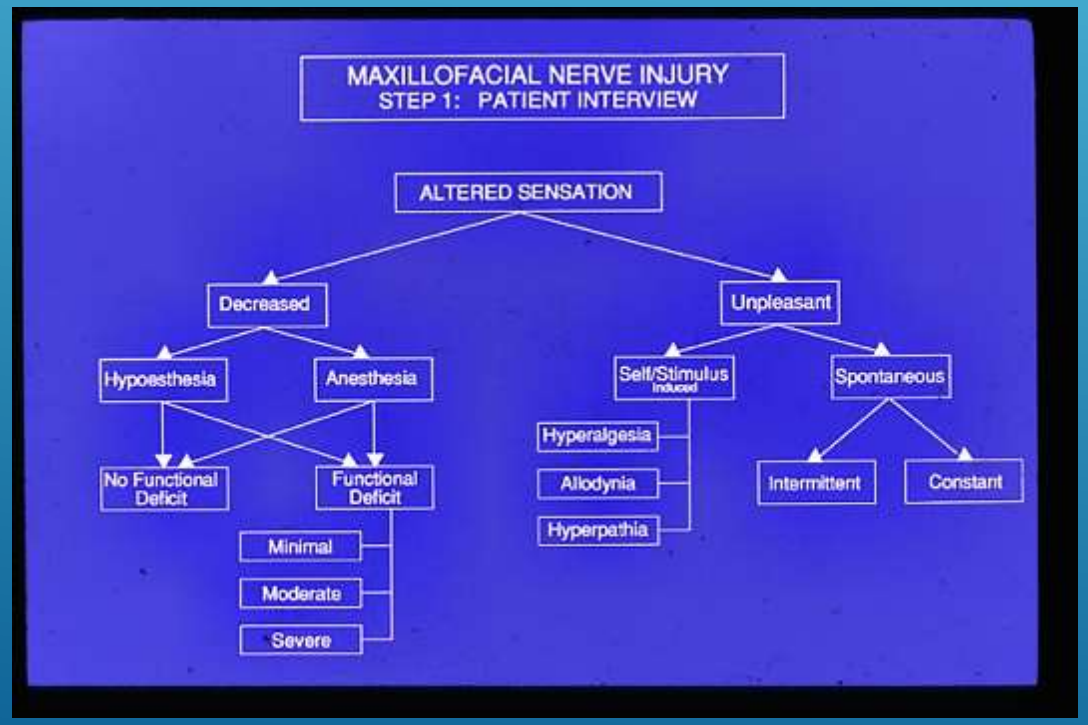

A. HISTORY AND PHYSICAL EXAMINATION

- Intraoral examination
- Self-injury
- Dystrophic changes



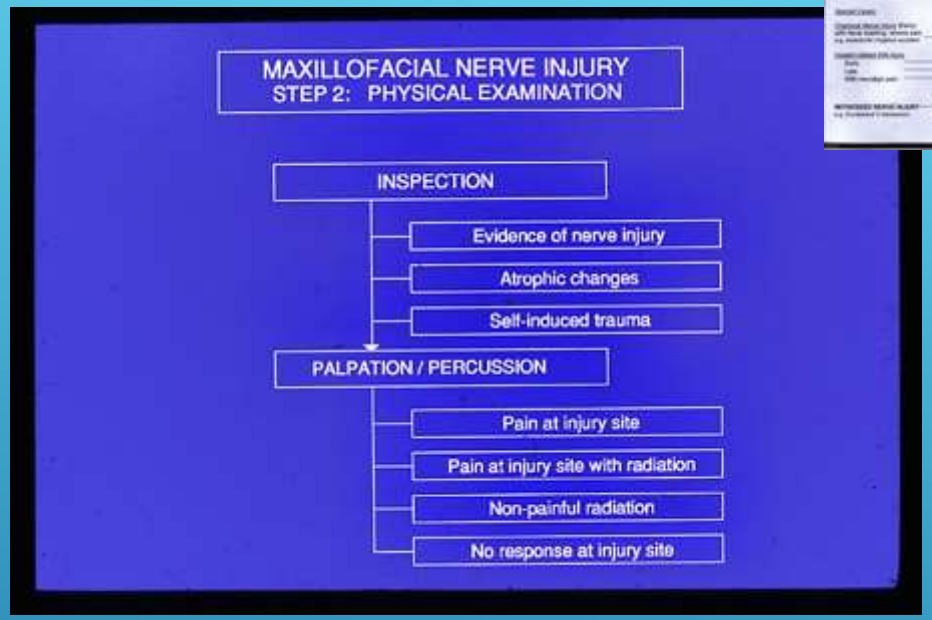

B. IMAGING OF NERVE INJURIES

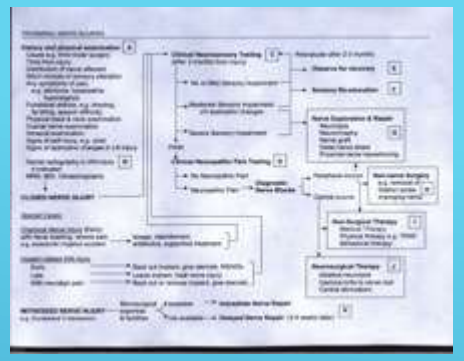

- Dental radiology
- CT/Cone Beam
- MRN/MRI

Get back to this real soon!

C. CLINICAL NEUROSENSORY TESTING

- *Sensory Impairment Score*
  - Normal
  - Mild
  - Moderate
  - Severe
  - Complete
- *Diagnosis*
  - Seddon
  - Sunderland



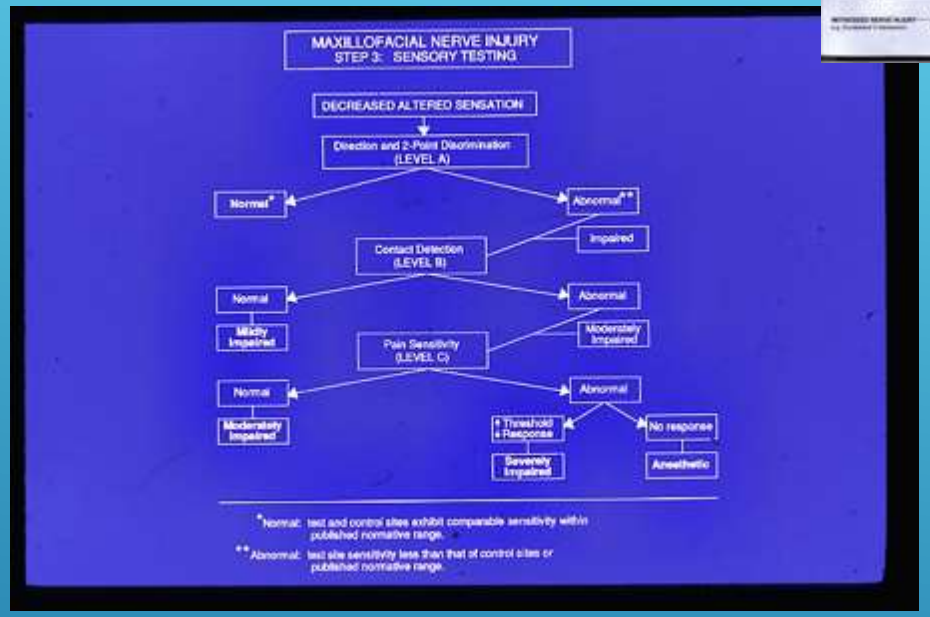

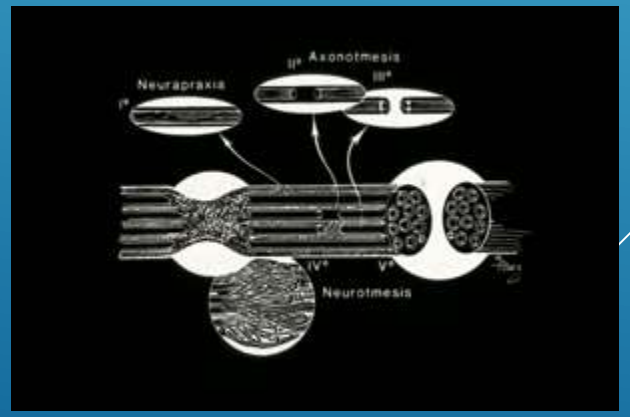

E/F: OBSERVE FOR RECOVERY/SENSORY RETRAINING



- Observe for Recovery
  - Most Nerve Injuries Resolved by 6 months
  - Rate of Regeneration in Man 1-2 mm/day
  - ***AGE***
  - ***Location of Injury***
  - ***Type of Injury***
  - ***Time from the Injury****

- Sensory Retraining
  - Class 1 and 2
  - Class 3

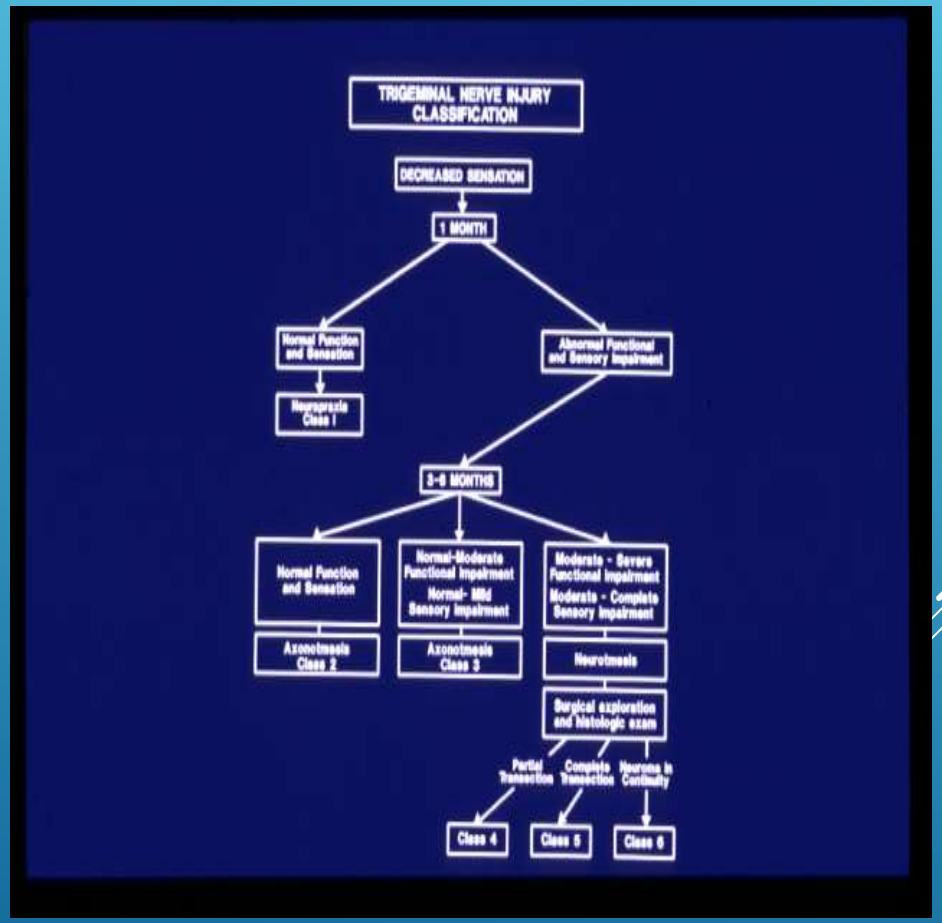

NERVE INJURY ASSOCIATED WITH THIRD MOLAR SURGERY

CONCLUSIONS *(BEFORE 2017)*

- **Observation is indicated**
  - For up to 3 months in unwitnessed injury
  - Hypoesthesia
  - Negative physical findings
  - No or mild sensory impairments
- **Surgery treatment is indicated**
  - Severe or complete sensory impairment up to or after 3 months (LN>IAN)
  - Negative word choices
  - Positive physical findings
- **Treatment varies**
  - Type of injury (class of injury)
  - Neuropathic pain

ZUNIGA, MEYER, GREGG, MILORO, DAVIS, JOMS 1998: THE ACCURACY OF CLINICAL NEUROSENSORY TESTING FOR NERVE INJURY DIAGNOSIS

- Determine the sensitivity, specificity and predictive values of the CNT using a 4-fold table with surgical findings as the "gold" standard
- Multisite, prospective, randomized, masked clinical trial
- Preoperative CNT and Sensory Impairment Score
- Postoperative surgical findings

NEUROSENSORY IMPAIRMENT SCORES

Patient Population

60 LN, 70 IAN

Male

IAN = 21

LN = 25

Female

IAN = 39

LN = 45

Duration of Injury (months)

Mean

IAN = 14.06±15.84

LN = 8.23±9.74

Range

IAN = 2-120

LN = 1-72

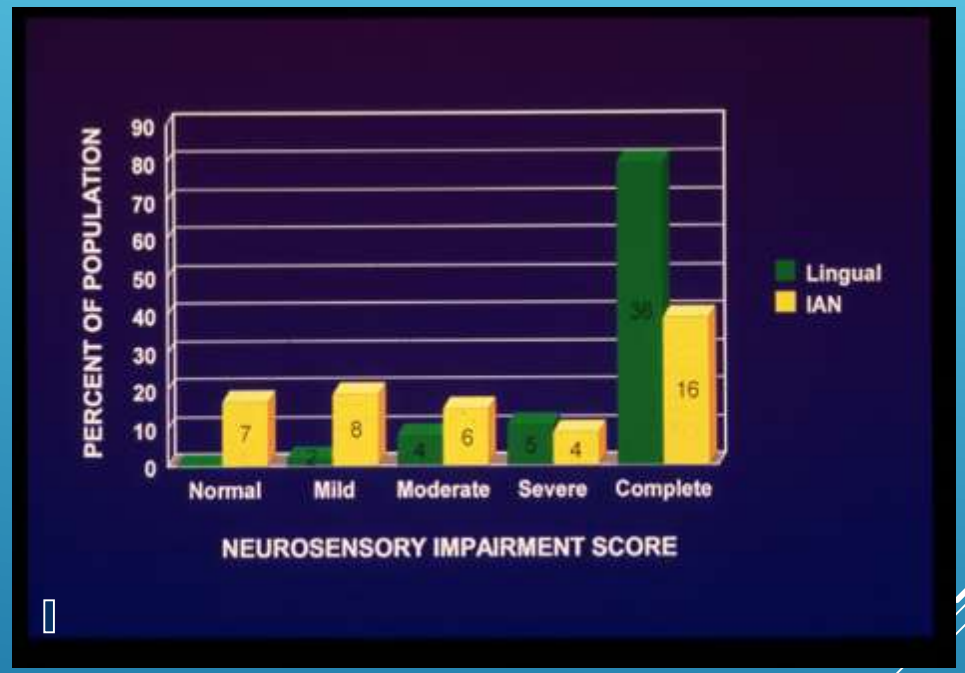

- More Diverse Distribution in IAN
- More homogenous in LN

NERVE INJURY SURGICAL FINDINGS

- Normal/Intact (N/I)
- Compressed/Intact (C/I)
- Neuroma-in-continuity (NIC)
- Partial Transection (PT)
- Complete Transection (CT)
- More Diverse Distribution in IAN injuries
- >80% of LN were Partial or Complete Transections

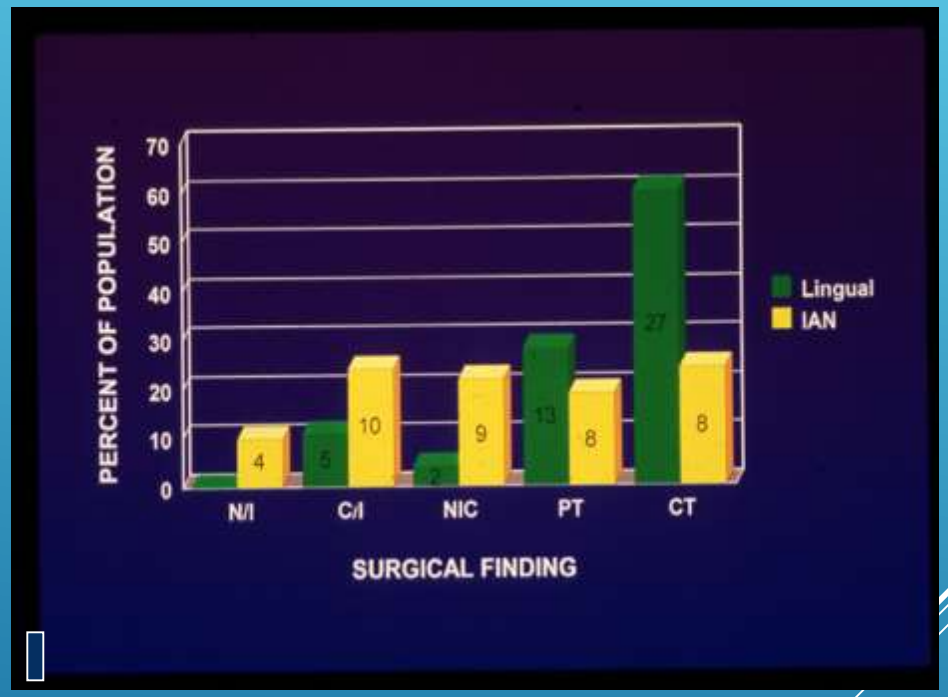

STATISTICAL RATES OF EFFICACY (%)

- Sensitivity
  - LN =100
  - IAN = 85
- Specificity
  - LN = 62.5
  - IAN = 47
- +Predictive
  - LN = 95
  - IAN = 77
- -Predictive
  - LN = 100
  - IAN = 60

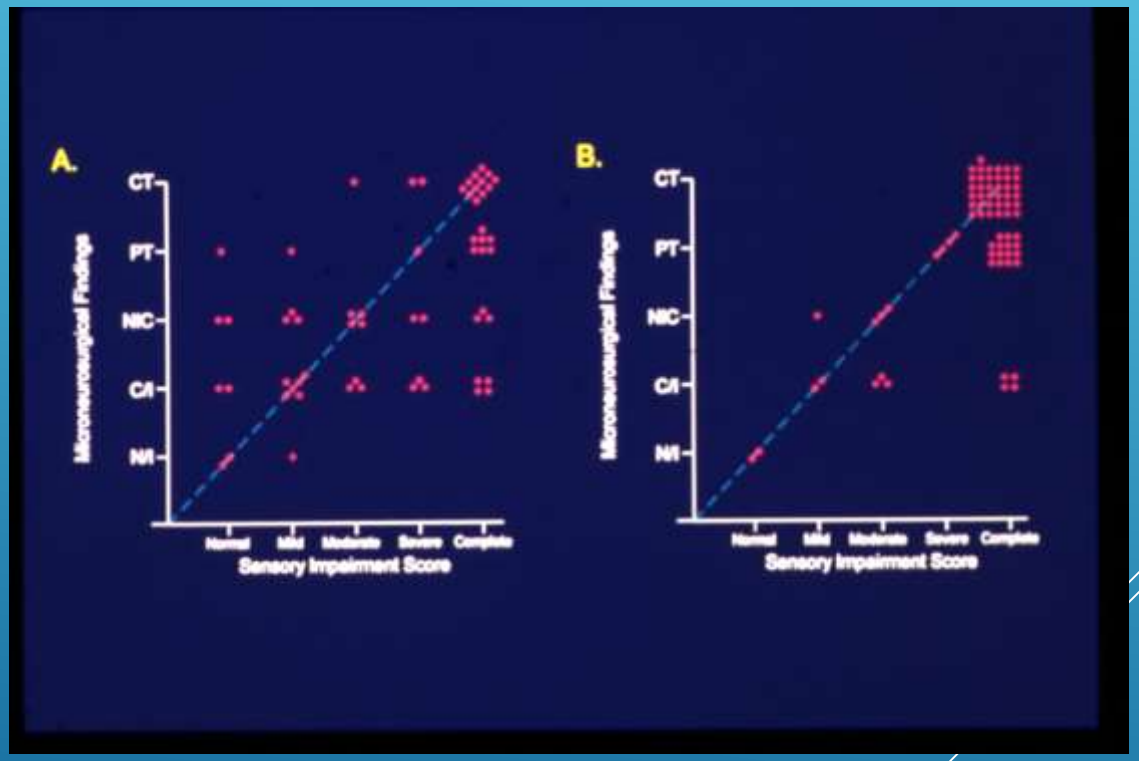

NOW WHAT?
TO DO OR NOT TO DO

CLINICAL NEUROSENSORY TEST
NST

- **Gold standard for diagnosis**
  - Inferior alveolar nerve ***(IAN)***
    - PPV 77%, NPV 60%
  - Lingual nerve ***(LN)***
    - PPV 95%, NPV 100%

- **Drawbacks to NST**
  - Delays treatment of higher class injury patients
  - Does not adequately delineate the anatomy and location of the injury
  - Can overestimate and underestimate the level of injury

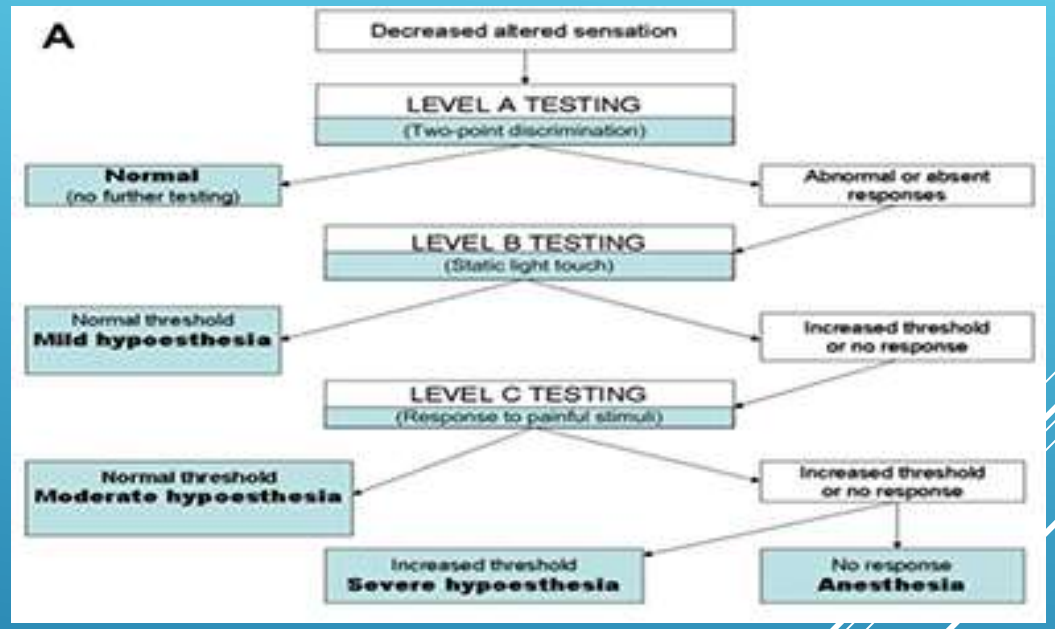

Role of Magnetic Resonance Neurography in the Management of Peripheral Trigeminal Neuropathy

- MR Neurography
  - **Magnetic resonance neurography (MRN)** is the direct imaging of nerves in the body by optimizing selectivity for unique MRI water properties of nerves. It is a modification of magnetic resonance imaging.
  - This technique yields a detailed image of a nerve from the resonance signal that arises from in the nerve itself rather than from surrounding tissues or from fat in the nerve lining.
  - 3D, steady state and diffusion based, includes T2W
    - Chabbra et al, J Magn Reson Imaging. 34:962-967, 2011
    - Chabbra et al, Semin Muskuloskeletal Radiol 19:79-85, 2015

- MRN Trigeminal Nerve
  - Terumitsu et al. OOOO 111:95-102, 2011
    - T1W MR sequences in 2D
    - Endoneurial fluid alterations
    - Intra-neural edema
    - Mass lesions

Purpose: *Evaluate a consecutive series of patients suspected of peripheral trigeminal neuropathy with MRN using a uniformed protocol to assess the correlation with surgical findings and impact of imaging in the clinical management*

MR IMAGING METHODS TO STUDY PERIPHERAL NERVE

- Anatomic MRN
  - 3 D reversed fast imaging with steady state precession (T2 PSIF)
  - Shows alterations of nerve caliber = quantitative criteria
  - Abnormal intraneural T2 signal intensity ratio (T2SIR)= qualitative criteria

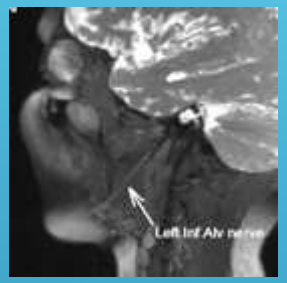

- Diffusion-based Functional MRN
  - Diffusion Tension Imaging (DTI) shows alignment of water within nerve = tractometry
  - Shows functional evaluation of the intraneural pathophysiology
  - Altered diffusion characteristics correlate with axonal degeneration and regeneration

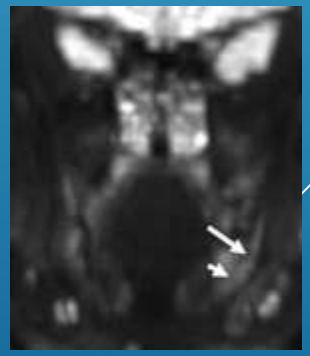

PERIPHERAL TRIGEMINAL MRN
NORMAL LEFT IAN

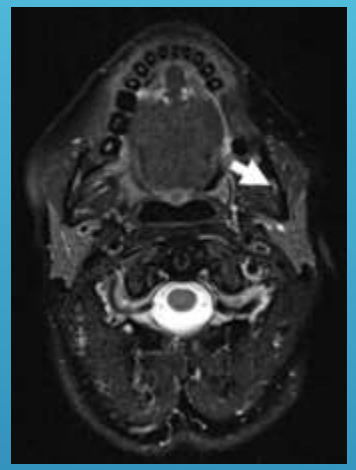

Axial T2 SPAIR
(non-vessel suppressed)

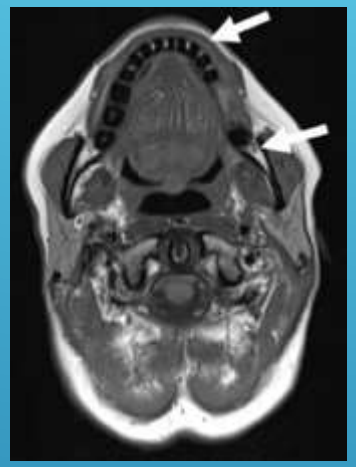

Axial T1W

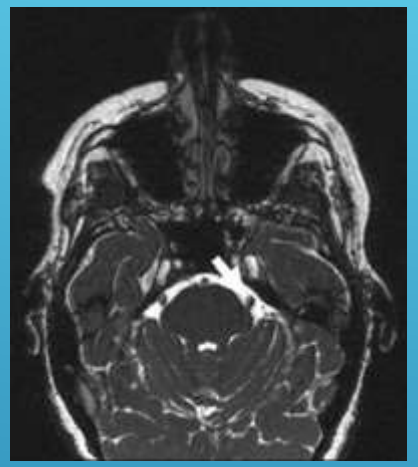

Axial CISS 3D

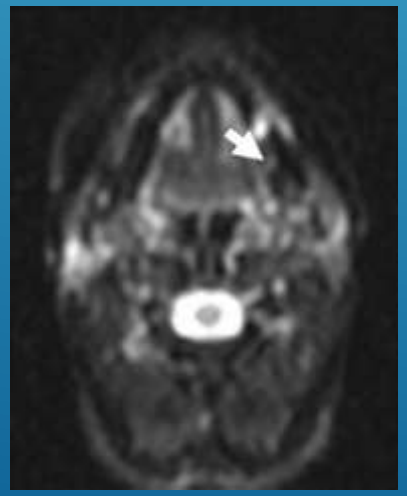

Axial DTI

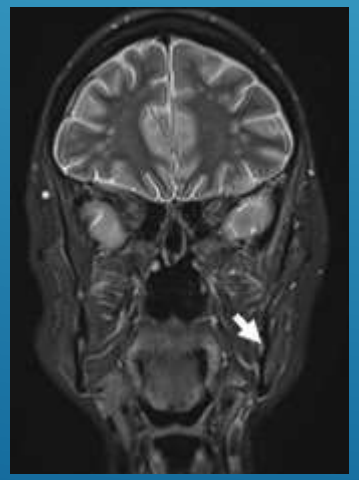

Coronal 3D STIR
SPACE
(non-vessel
suppressed)

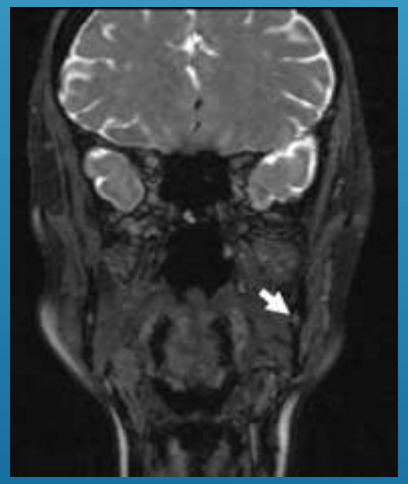

Coronal 3d DW
PSIF
(vessel-
suppressed

Sagittal oblique from
3D DW PSIF

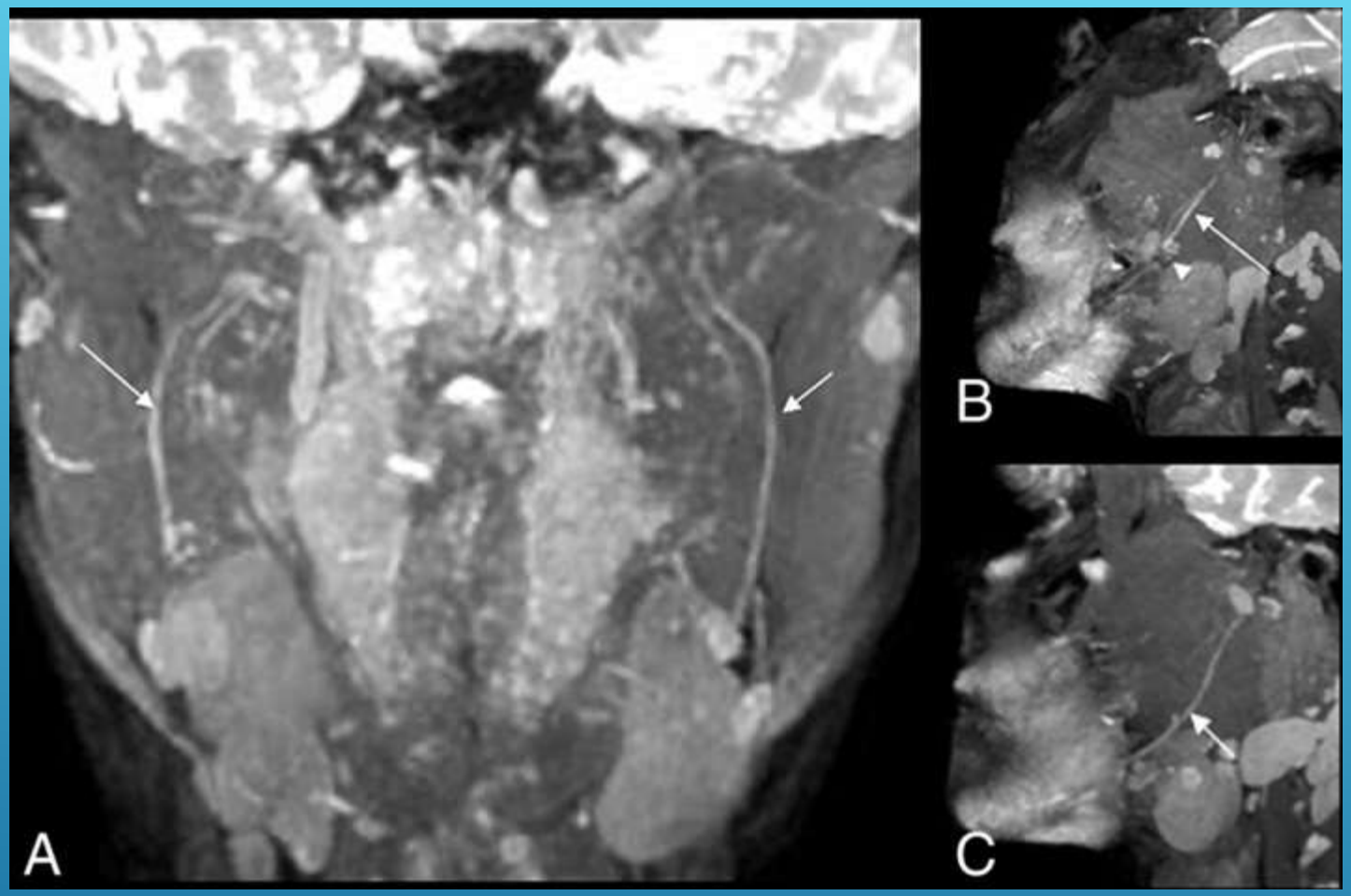

A, MIP coronal 3D PSIF image showing class II injury to the right IAN with mild increase in caliber (less than 50% of the left) and signal intensity of the right IAN (*long arrow*) in comparison with a normal left inferior alveolar nerve (*short arrow*). *B*, Sagittal reconstruction MIP 3D PSIF image showing increase in caliber and signal intensity of the right IAN (*long arrow*) proximal to injury site (*arrowhead*). *C*, Normal uniform caliber and signal intensity of the left IAN (*short arrow*).

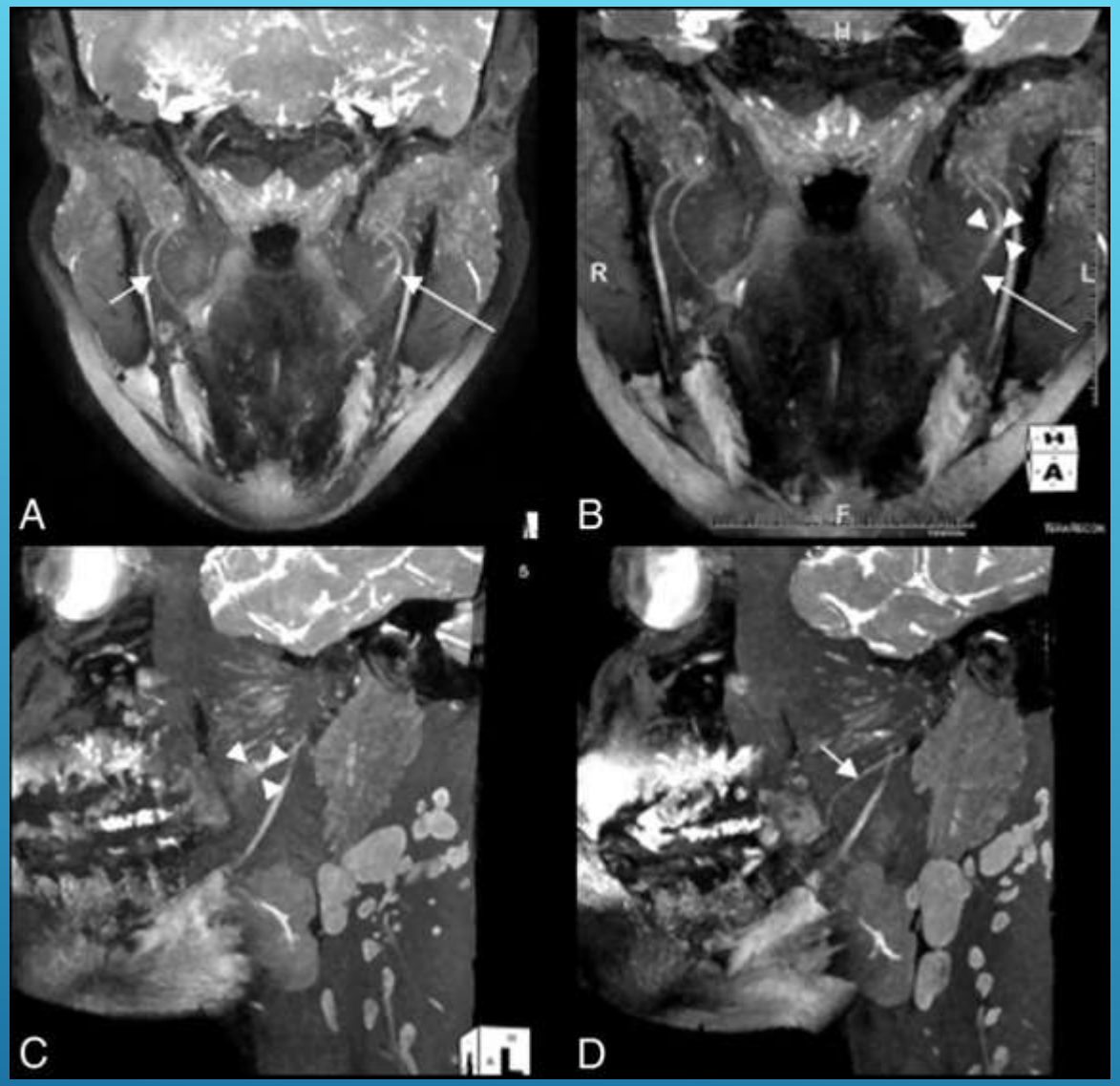

A and *B*, MIP 3D coronal PSIF images show a hyperintense left LN (*long arrow*) with a 3-mm neuroma in continuity (demarcated by 3 *arrowheads*) compatible with class IV injury. *C* and *D*, Sagittal reconstructions show the abnormal left LN neuroma (demarcated by 3 *arrowheads*) compared with a normal right LN (*short arrow*).

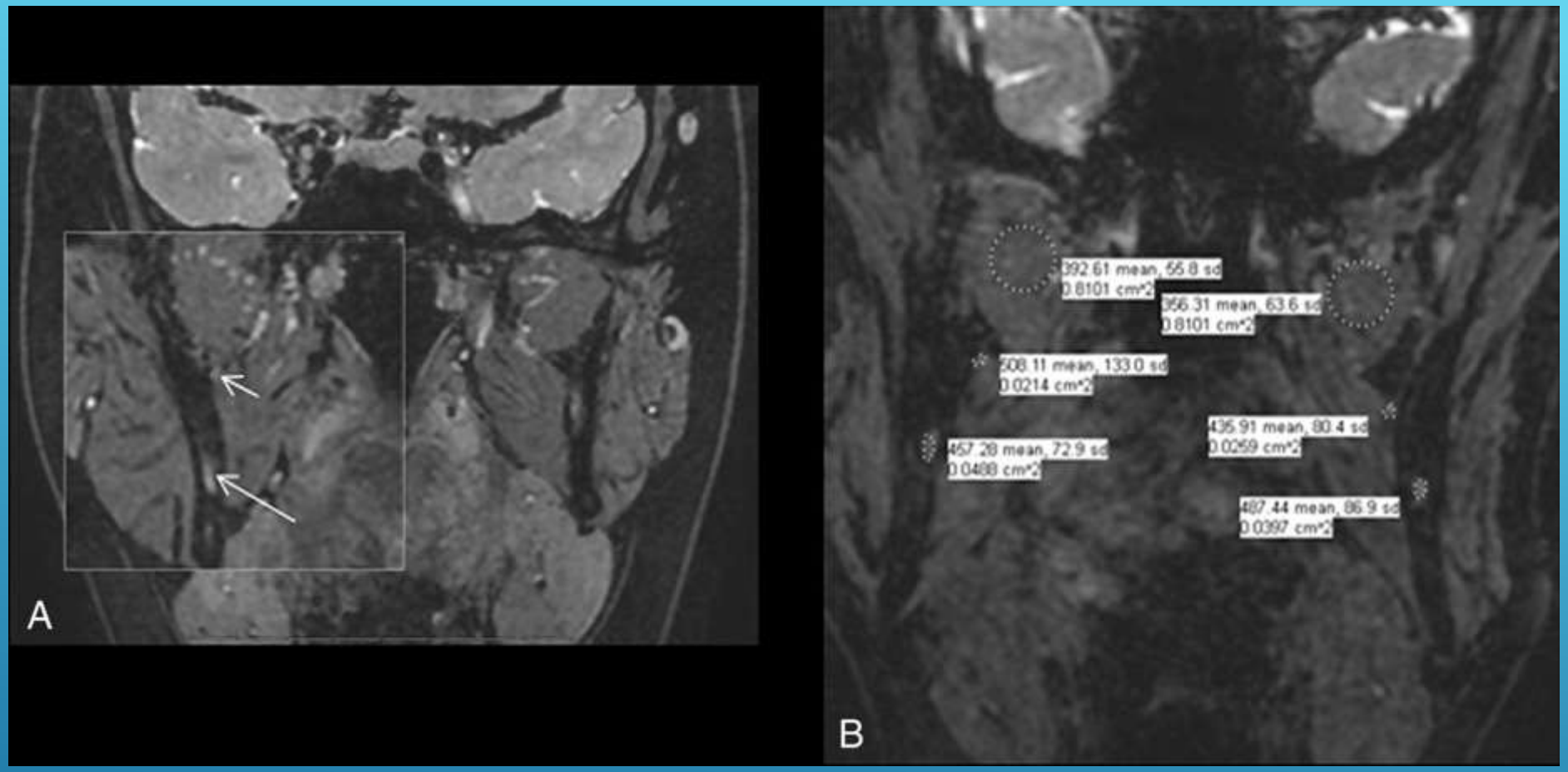

Coronal 3D PSIF images showing *A*, localization of the site of the LN and IAN (*short* and *long arrows*, respectively) and *B*, signal intensity measurements on both sides.

METHODS

Patient Pool

- Retrospective
  - 20 months (2013 – 2014)
- 17 patients
  - 10♂;7♀
  - 43.4 ± 18.7 years
  - Symptoms = 2.2 ± 4 years (2 weeks to 17 years)
- 2 surgeons
  - OMS and PRS
- TN distribution
  - IAN = 13
  - LN = 2
  - Both = 7

Patient	Age	Sex	Inciting event	Duration of symptoms (months)	Pain	Other sensory symptoms	Motor symptoms	Palpable mass
1	58	F	Surgery	48	Y	Y	N	Y
2	48	M	Surgery	1.5	N	Y	N	N
3	55	M	Surgery	36	Y	Y	N	N
4	69	F	Surgery	6	Y	Y	N	N
5	14	F	Surgery	2	N	Y	Y	N
6	46	F	Surgery	8	Y	N	N	N
7	27	F	None	3	Y	Y	N	N
8	61	M	None	2	N	Y	N	Y
9	26	F	Surgery	36	Y	Y	N	N
10	20	M	Surgery	48	Y	Y	Y	N
11	62	F	Surgery	2.5	Y	Y	N	N
12	57	M	None	204	Y	Y	N	N
13	38	M	Surgery	0.5	Y	Y	N	N
14	54	M	Trauma	7	Y	N	N	N
15	29	F	Surgery	8	Y	Y	N	Y
16	43	F	None	3	Y	Y	N	N
17	60	F	Surgery	38	Y	Y	N	N

Imaging

- 1.5 Tesla Scanner
  - Siemens, avanto, erlanger
- No contrast
  - 1 exception (mass effect)
- Duration = 45 minutes
- Evaluations
  - 3D manuevers
    - Axial, longitudinal, coronal
  - Thick slab max intensity projection
  - 2 readers, blinded
  - CISS 3D sequences
  - T1W & T2W SPAIR sequences STIR SPACE (non-vessel suppressed) and DW PSIF (vessel-suppressed nerve selective)
    - Corpus collosum to chin

Sequence	TR (ms)	TE (ms)	Flip angle	Matrix	FOV/Other
Axial T2 SPAIR	3200	80	111	320x280	Corpus collosum to chin Slice 1.00 mm
Axial T1W	710	8.7	111	320x280	Corpus collosum to chin
Axial CISS 3D	3.12	2.46	111	256x256	Submandibular area to C2 vertebral level
Axial DTI	7100	80	4	74x74	Skull base to chin Prefixes: 0,400,1200; Directions: 12
Coronal T2 STIR SPACE	3000	70	111 sec	320x200	Corpus collosum to chin
Coronal T2 DW PSIF	11	1.21	111 sec	256x200	Corpus collosum to chin

Sec: MRI- magnetic resonance sonography, T-Tesla, sec-isotropic in- weighted, TR- Repetition time, TE- Echo time, ms- milliseconds, mm- millimeter, C- cervical, SPAIR- Spectral adiabatic inversion recovery, CISS- constructive interference in steady state, 3D- 3dimensional, STIR- short tau inversion recovery, SPACE- sleek pulse 3D acquisition with variable excitation flip angle evolutions, DW- Diffusion weighted, DTI- Diffusion tensor imaging, PSIF- reversed steady state in free precession

DATA ON MRN

Image Results	Impact on Management	Surgical Correlations
Normal	None no change in diagnosis no change in nerve involved no change in treatment strategy	Poor No correlation
Entrapment	Mild change in diagnosis or nerve involved no change in treatment strategy	Moderate Partial correlation
Injury	Substantial change in diagnosis or nerve involved change in treatment strategy	Excellent Full correlation

PATIENT #11

62 Y/O FEMALE 2.5 MONTHS WITH PAINFUL NEUROPATHY LEFT IAN

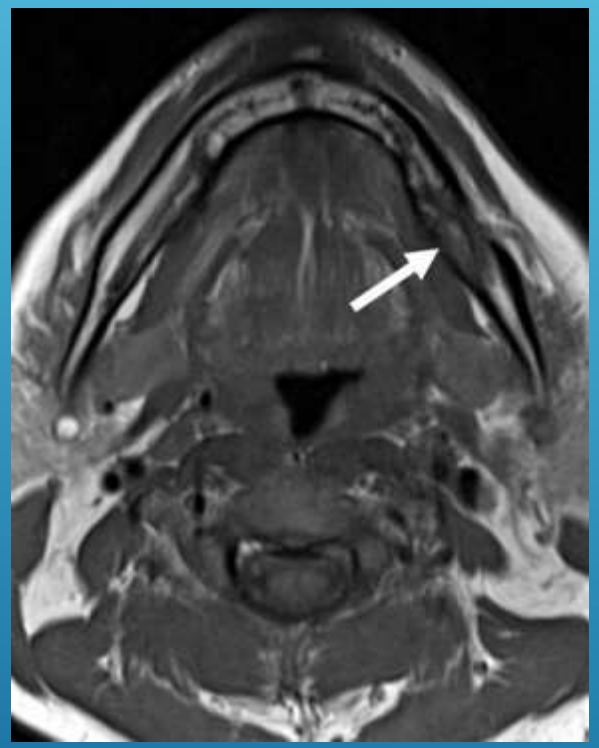

Axial T1W – perineural fibrosis

Coronal 3D DW PSIF – thickening and hyperintense with mild contour changes due to entrapment

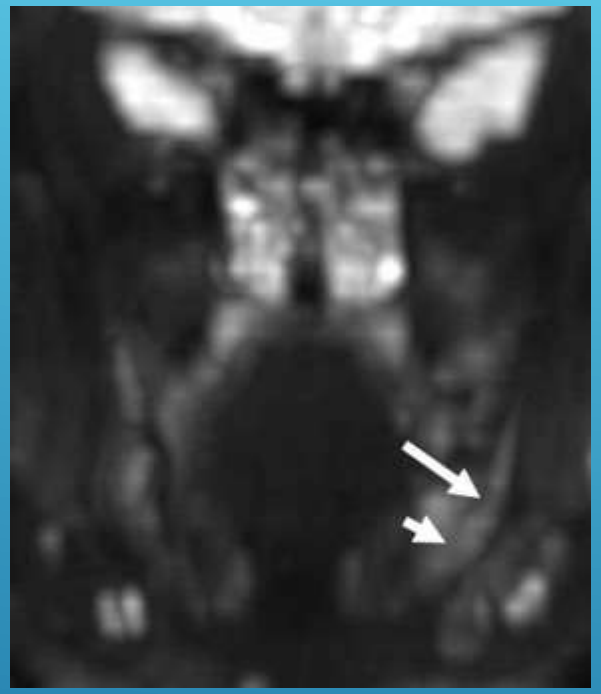

Same in DTI

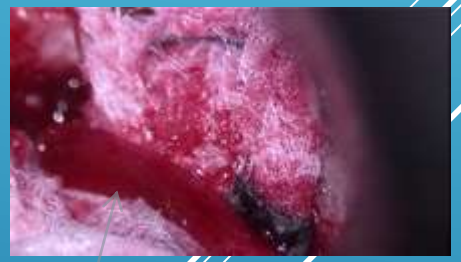

Left inferior alveolar nerve

PATIENT #9

26 Y/O FEMALE WITH PAINFUL NEUROPATHY RIGHT IAN AND NON-PAINFUL NEUROPATHY RIGHT LN

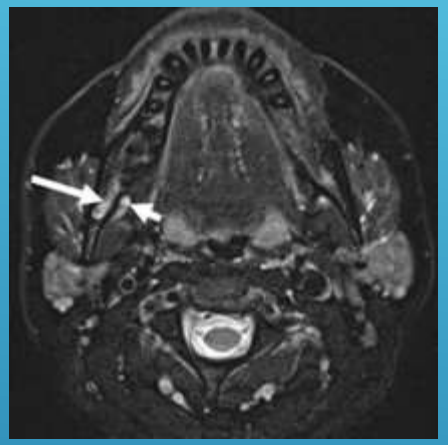

Axial T2 SPAIR – thickening and hyperintensity right IAN and LN with small NIC (arrow)

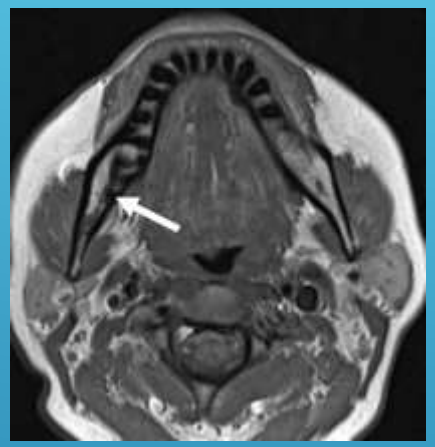

Axial T1 – perineural fibrosis and thickening of IAN

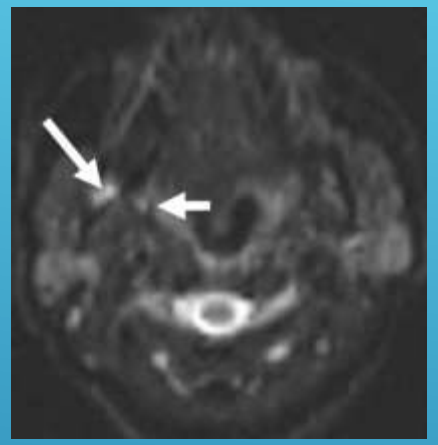

Axial DTI - confirms

3D DW PSIF –NIC of LN

LN surgical findings

IAN surgical findings

PATIENT #2

48 Y/O FEMALE, 1.5 MONTHS INJURY NON-PAINFUL NEUROPATHY LEFT LN

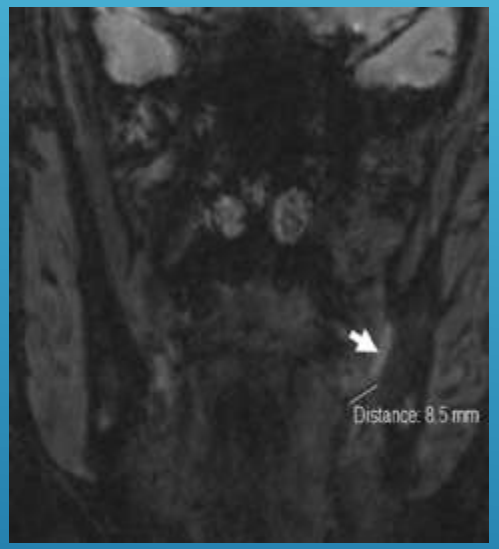

Coronal 3D DW PSIF – enlarged thickened and discontinuous with nerve gap = 8.5mm

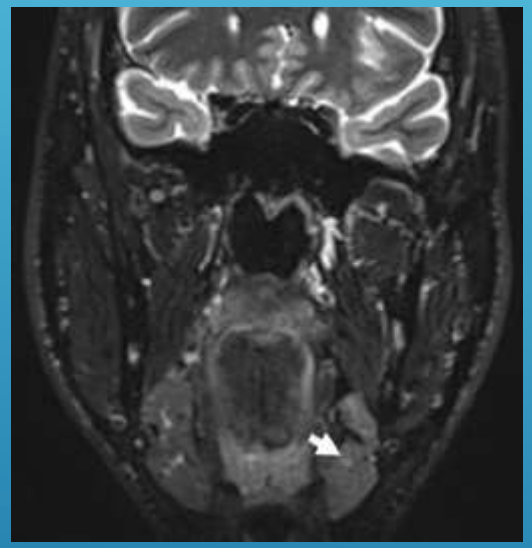

Coronal 3D STIR SPACE – hyperintensity left submandibular gland (arrow)

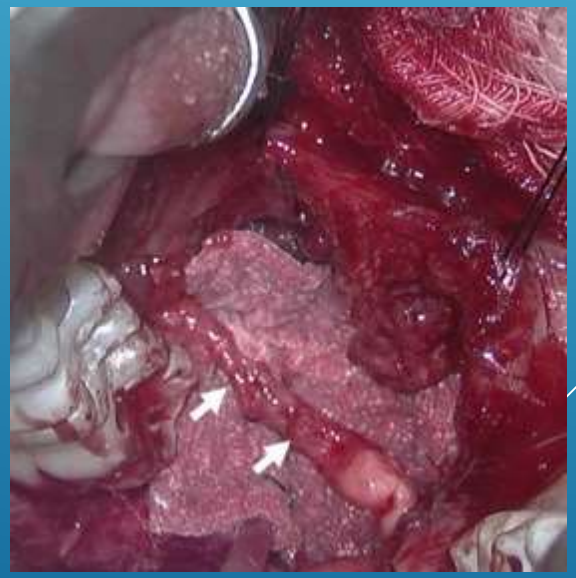

LN surgical findings = 12mm

- 45 y/o Female s/p 2 months #17 extraction with severe sensory impairment, positive trigger, dystrophic ageusia and burning, consistent with Class IV injury left lingual nerve

3D MIP

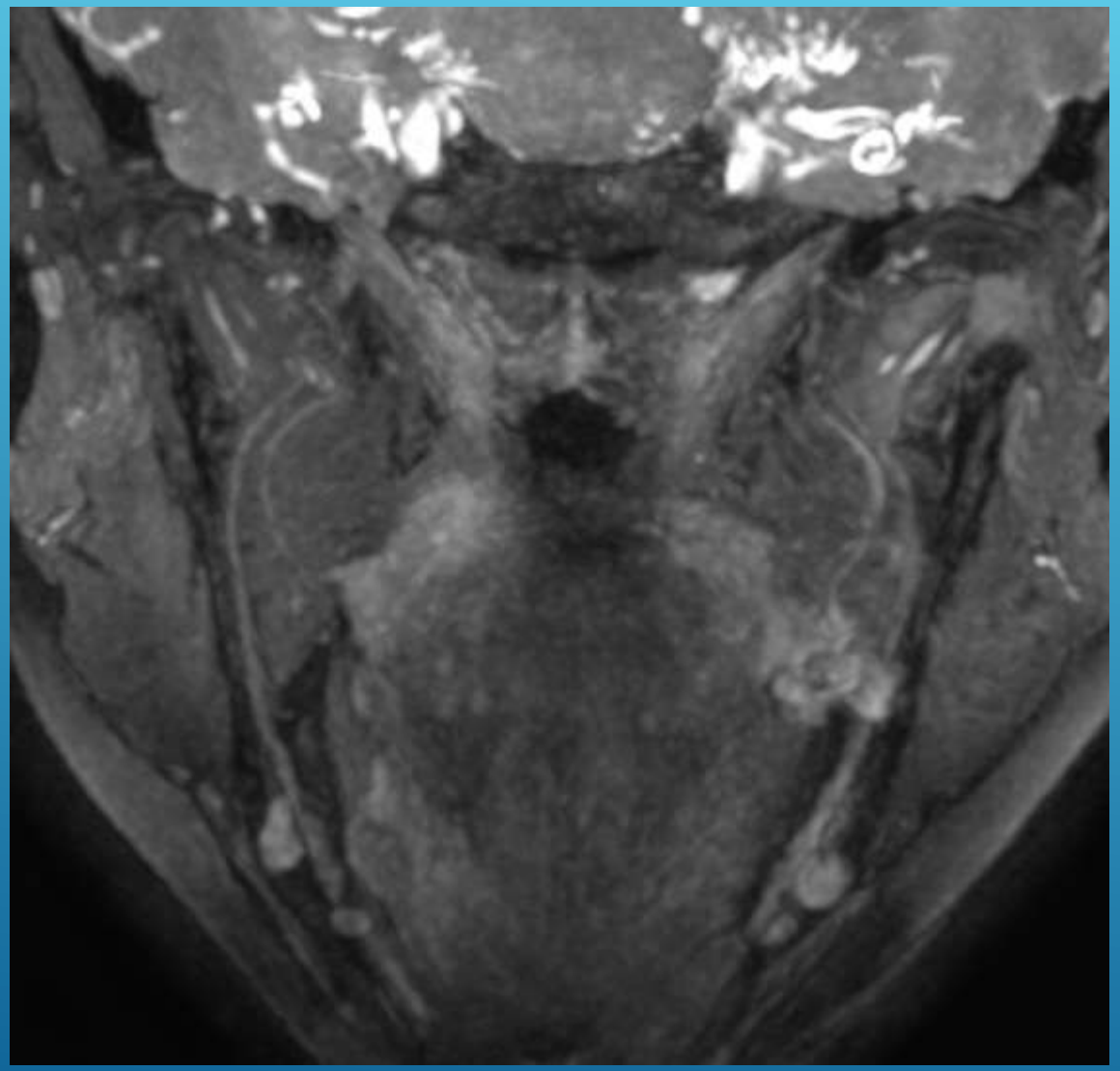


92237929
6/9/16
Left lingual Class IV/V injury
16 mm gap defect

3D MIP

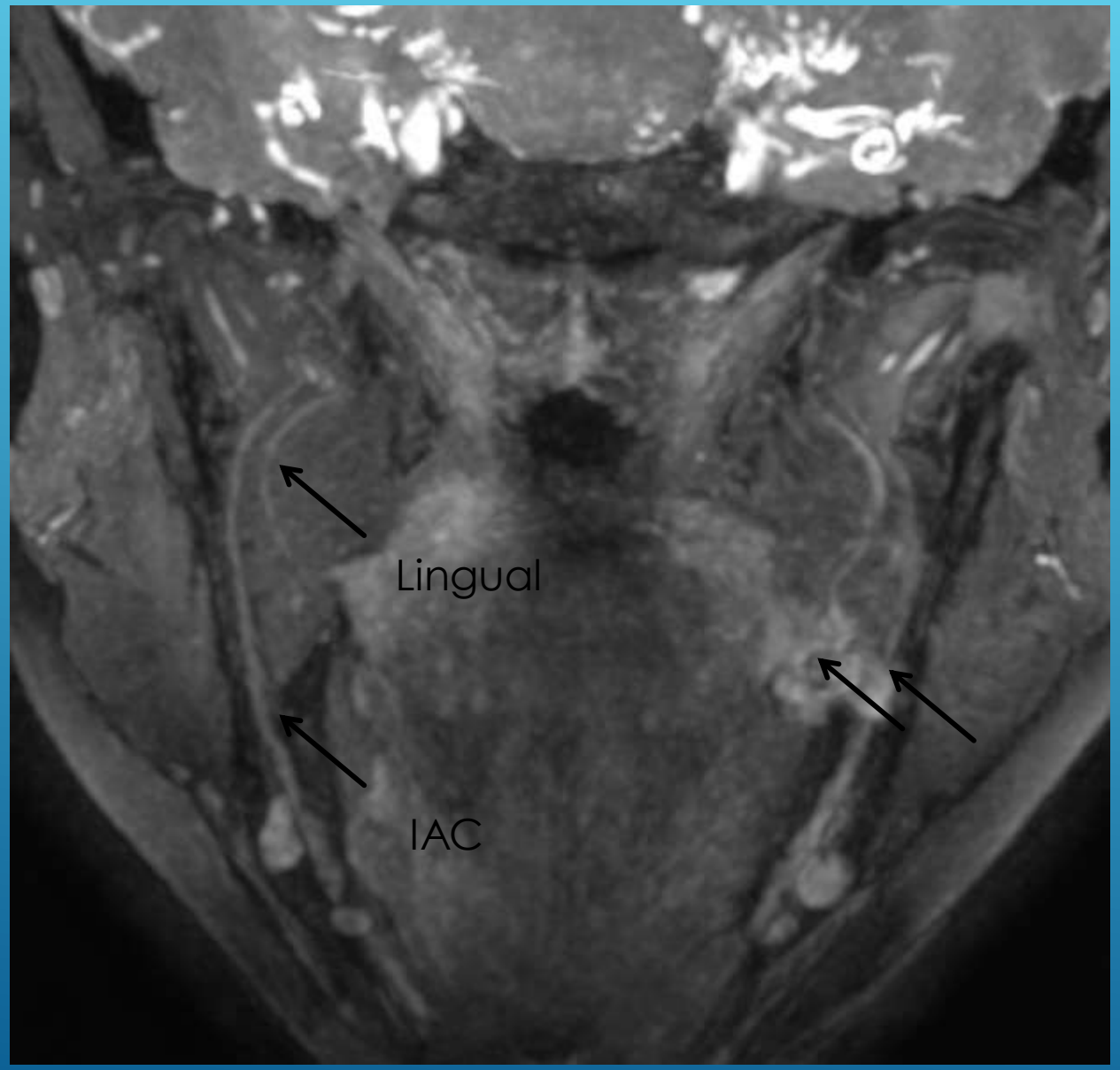
Lingual
IAC

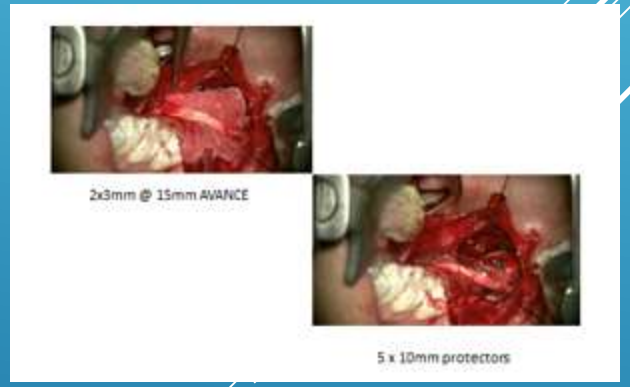
2x3mm @ 15mm AVANCE
5 x 10mm protectors

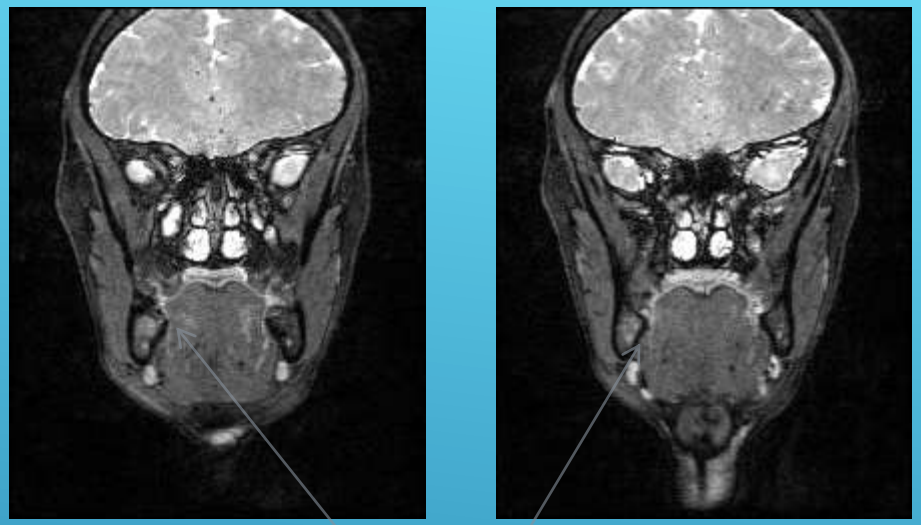

COR PSIF

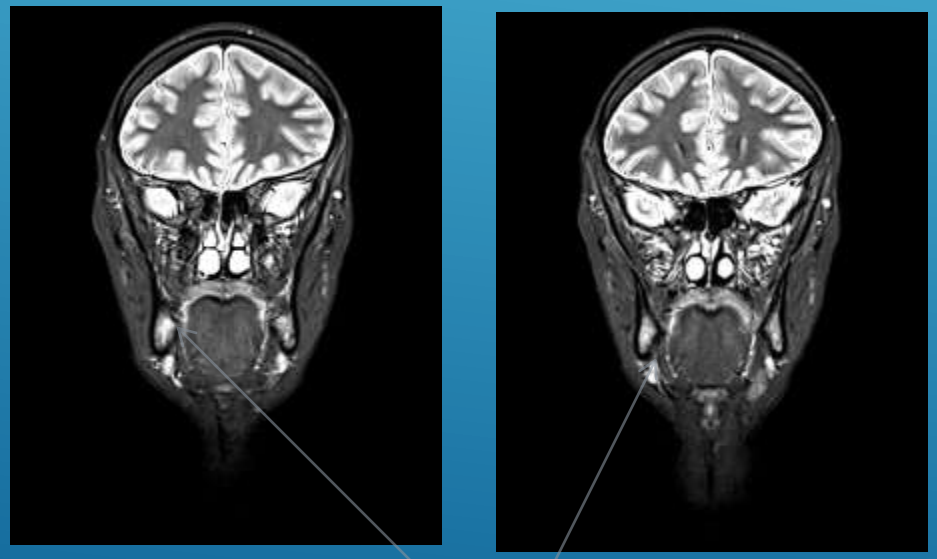

3D COR STIR

91537885

25 year old 17 months s/p right lingual nerve repair with allograft

Normal S4 outcomes

"85% back but worried about possible neuroma coming back"

IMPRESSIONS: MR Neurography 11/30/2015

The right lingual nerve is mildly prominent with adjacent susceptibility artifacts reflecting postoperative changes. No focal neuroma identified

RESULTS

Imaging Results	Impact on Management	Surgical Correlation
Diffuse nerve thickening 12/17	None = 5/17	Moderate/Excellent = 7/17
Focal Mass = 4/17	Mild = 6/17	False Positive = 1
Perineural fibrosis = 7/17	Substantial = 6/17	
Diagnosis normal = 3/17 neuritis = 4/17 scar entrapment = 3/17 neuroma IC = 2/17 transection = 1/17		
• No pathology on contralateral side		
• Submandibular & sublingual gland – edema		

ACKNOWLEDGEMENTS

Department of Radiology, UTSW
Avneesh Chabbra, MD
Brian Cox, MD
Riham Dessouky, MD

Division of Oral and Maxillofacial Surgery, UTSW
John Zuniga, DMD, MS, PhD

Department of Oral and Maxillofacial Surgery, UPENN
Neeraj Panchal, DDS, MD

Department of Plastic Surgery, UTSW
Jonathan Cheng, MD

Department of Neurological Surgery, UTSW
Jonathan White MD

Department of Otolaryngology, UTSW
Larry Myers MD

Cox, B, **Zuniga JR,** Panchal N, Cheng J, Chabbra A: *Magnetic resonance neurography in the management of peripheral trigeminal neuropathy: experience in a tertiary care center*. ***European Radiology, 10:3392-3400, 2016***

Dessouky R, Xi Y, **Zuniga J**, Chhabra A: Role of Magnetic Resonance Neurography (MRN) for the Diagnosis of Peripheral Trigeminal Nerve Injuries in Patients with Prior Molar Tooth Extraction. ***Am J Neuro Radiol, 39 (1) 162-169, 2018***

Chhabra A, Bajal G, Wadhwa V, White J, Myers L, Bardia A, **Zuniga J:** Magnetic Resonance Neurography Evaluation of Facial and Neck Pain: Normal and Abnormal Lower Craniospinal Nerves Below the Skull Base. : ***Radiographics, 39:1498-1513 2018***

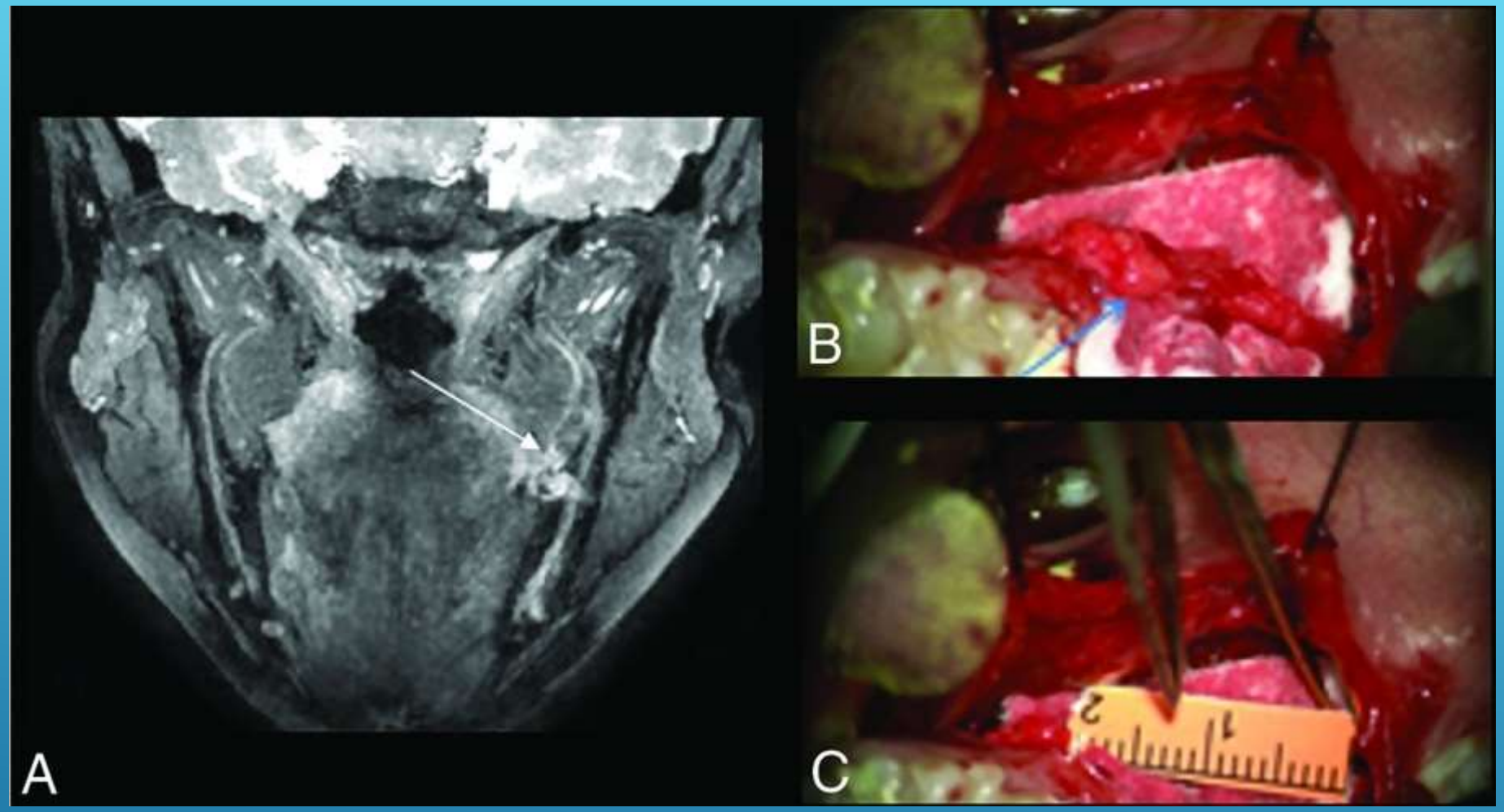

A, MIP 3D PSIF coronal image shows class IV/V injury of the left LN with excessive granulation and possible discontinuity of its distal end (*long arrow*). *B*, On surgery, it was also called class IV/V injury (*arrow*) with excessive scarring and granulation tissue and was resected. The final gap was 16 mm (*C*) and an allograft was placed for nerve reconstruction.

MRN – IAN AND LN INJURY IN THIRD MOLAR EXTRACTIONS

- 42 patients (24 cases, 18 controls)
  - 35.8±10.2 years
  - ♂ to ♀ =1:1.4
- Nerve injury demographics
  - 25 injuries found
  - 18 LN/7 IAN
  - NST = class II (2); Class III (4); Class IV (4); Class V (1)
  - 13 had surgery performed
- Imaging
  - T2 PSIF and DTI on 1.5 and 3.0 T
- Interpretation and analysis on T2 PSIF
  - Readers blinded
  - Nerve thickness = max transverse of IAN in midcanal, LN in midcourse
  - Signal intensity= same area ROI at most visible abnormality
  - T2SIR = SI nerve /√SI nerve) and CNR (SI nerve — SI pterygoid muscle/√SI nerve)
  - Fisher exact and Wilcoxon rank sum test for demographic values
  - AUC – using receiver operating characteristics of MRN accuracy in detection of neuropathy
  - κ analysis to test correlation of sunderland classification on NST, MRN and Surgical findings
  - Pearson correlation coefficient for differences in thickness between normal and abnormal nerve
  - Intraclass correlation coefficients to assess interobserver performance

SUNDERLAND NERVE CLASSIFICATION BY NST, SURGICAL FINDINGS AND MRN IMAGING

3D MIP

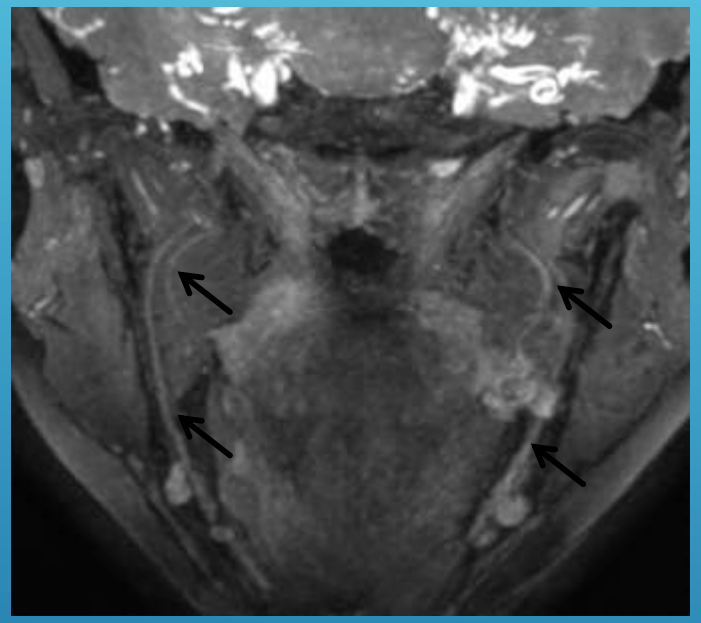

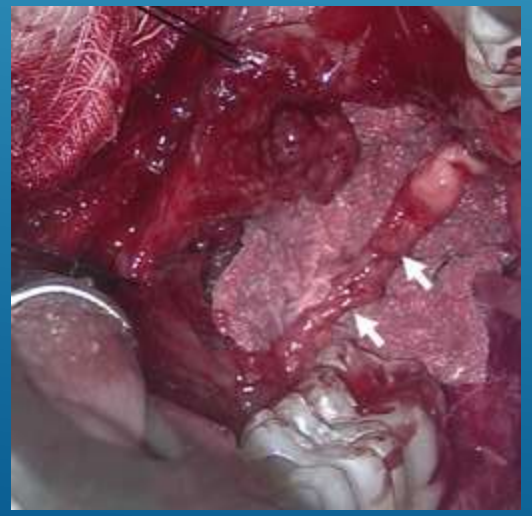

Sunderland Classification	Clinical NST level and MRCS Grade Description	Surgical by Direct inspection	MR Neurography
I	Normal (4)/ S3+ or S4 by 3 months	Intact with no internal or external fibrosis, normal mobility and neuroarchitecture (visualized fascicles and fanconi bands)	Anatomic: Homogenous increased T2 signal of nerve. Diffusion: Normal FA and ADC. Tractography: Symmetrical and normal tracts
II	Normal (4)/ S3+ or S4 by 6 months	Intact with no internal fibrosis. External fibrosis, restricted, mobility but neuroarchitecture intact (visualized fascicles and fanconi bands once external scar removed	Anatomic: Homogenous increased T2 signal of nerve and mild nerve thickening or constriction. Perineural fibrosis Diffusion: Decreased FA and increased ADC. Tractography: Normal or mild asymmetry of tracts
III	Mild (3) or Moderate (2)/S2, S2+, S3 by 6 months or more	Intact with both internal and external fibrosis, restricted mobility and disturbance of neuroarchitecture (abnormal fascicle patterns and/or fanconi bands not visible)	Anatomic: Homogenous increased T2 signal of nerve and moderate thickening or constriction. Perineural fibrosis Diffusion: Decreased FA and increased ADC Tractography: Partially disrupted tracts
IV	Moderate (2) or Severe (1)/S1, S2, S2+ by 6 months or more	Partial transected nerve but some amount of distal nerve present with or without neuroma in continuity	Anatomic: Heterogeneous T2 signal of nerve and neuroma in continuity. Perineural and intraneural fibrosis. Diffusion: Decreased FA and increased ADC. Tractography: Partially disrupted and disorganized tracts
V	Severe (1) or Complete (0)/S0, S1 by 6 months or more	Complete transected nerve with or without amputation neuroma	Anatomic: Discontinuous nerve with end-bulb neuroma Diffusion: Decreased FA and increased ADC. Tractography: Completely disrupted tracts



κ = 0.57

κ= 0.4

κ correlations for *A*, MRN versus NST and *B*, MRN versus surgical classifications.

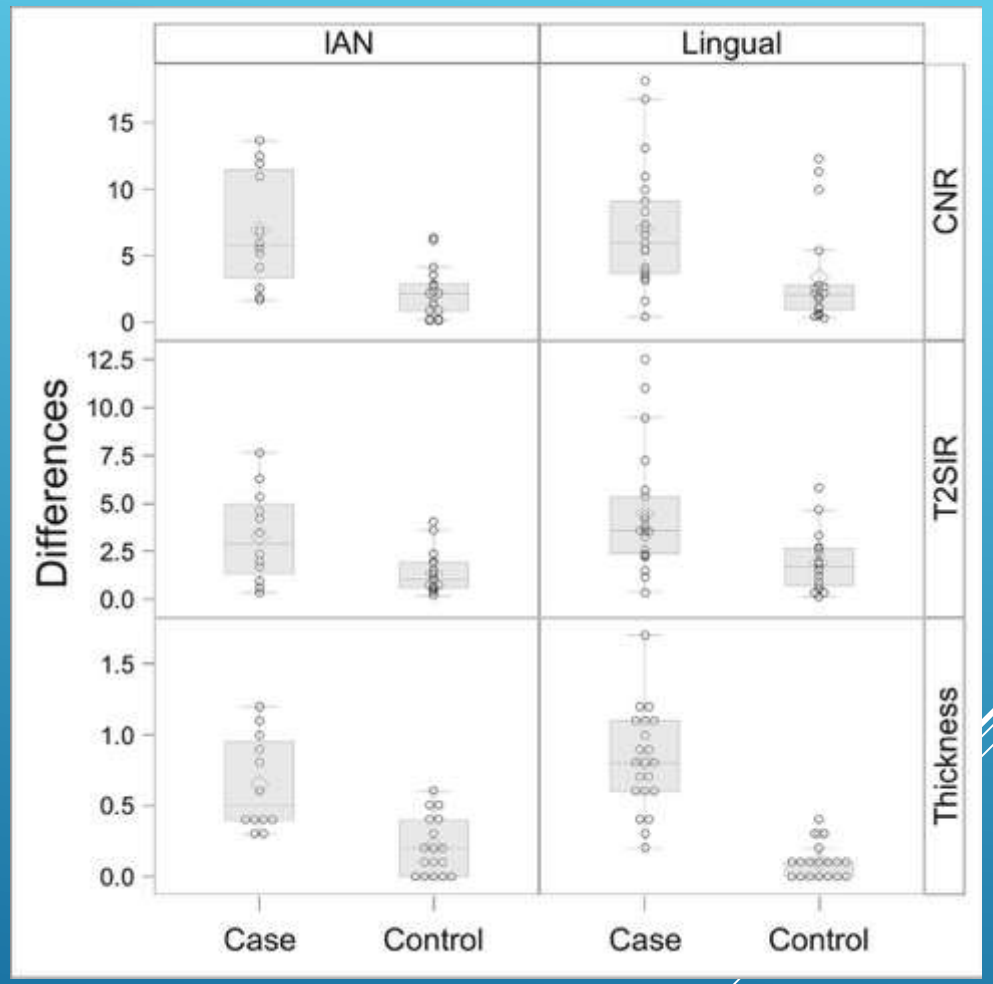

P = 0.1 both

P= 0.12 IAN
P= 0.005 LN

P=0.01 IAN
P= 0.0001 LN

Differences in thickness, T2SIR, and CNR among the case and control groups.



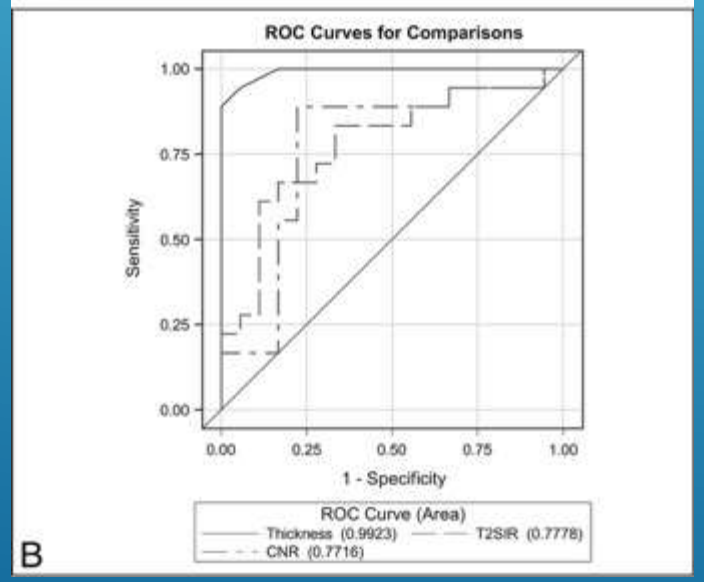

ROC curves for *A*, IAN and *B*, LN.

Accuracy of:
CNR = 0.83
T2 SIR = 0.84
Thickness = 0.99

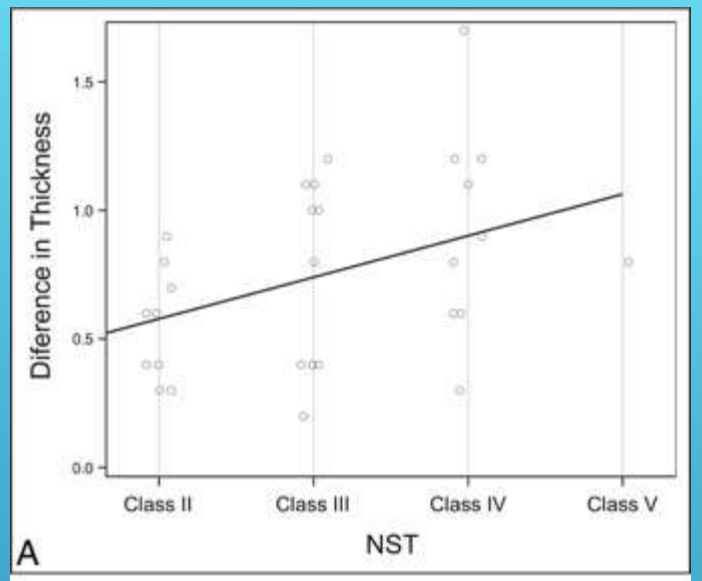

PCC = 0.68

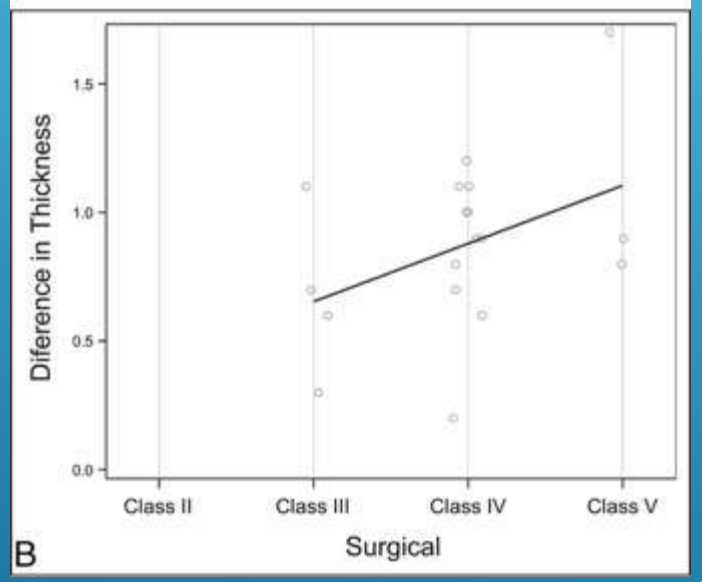

PCC = 0.81

Correlations between differences in nerve thickness on MRN versus NST (*A*) and surgery (*B*).

92832114
DOS = 7/21/17

Young female

Right lingual nerve , third molar extraction injury >8 months
Neurosensory testing=Moderate impairment/ S2 = Class III or IV injury

NOT TO SCARE- BUT THIS IS HOW SUBTLE THESE LESIONS CAN BE..

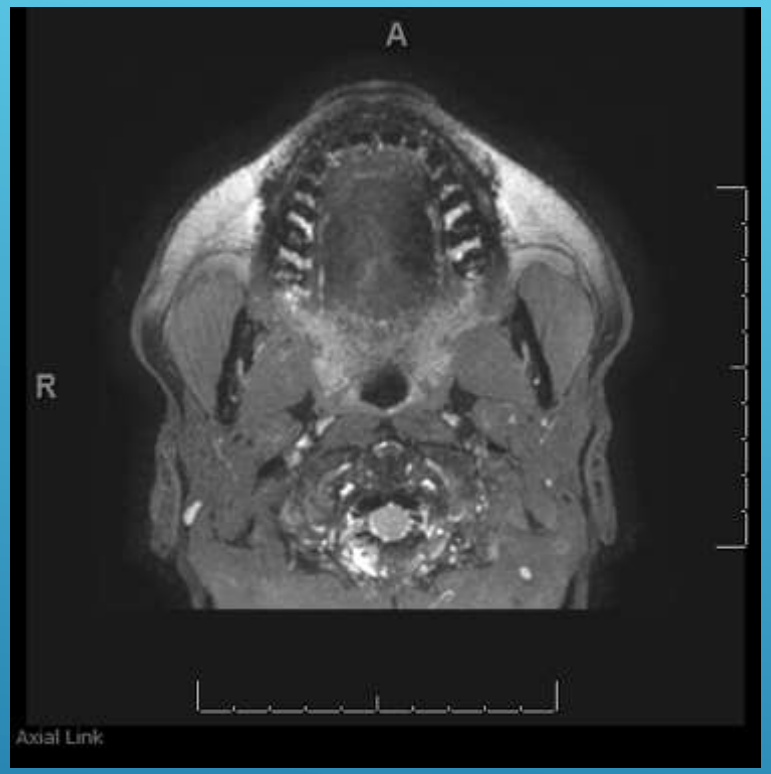

92832114
DOS = 7/21/17

DTI

92832114
DOS = 7/21/17

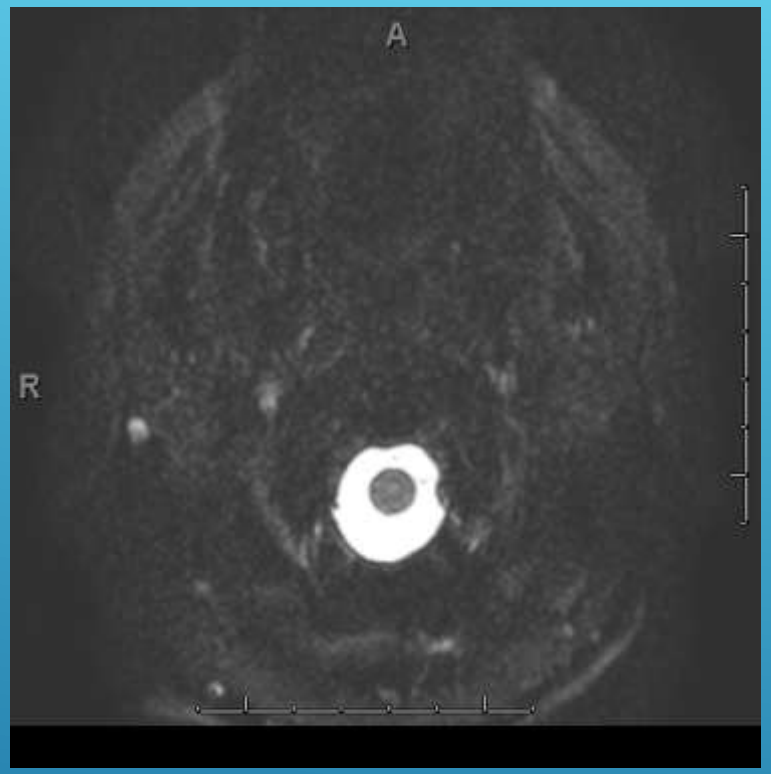

3D shows it better

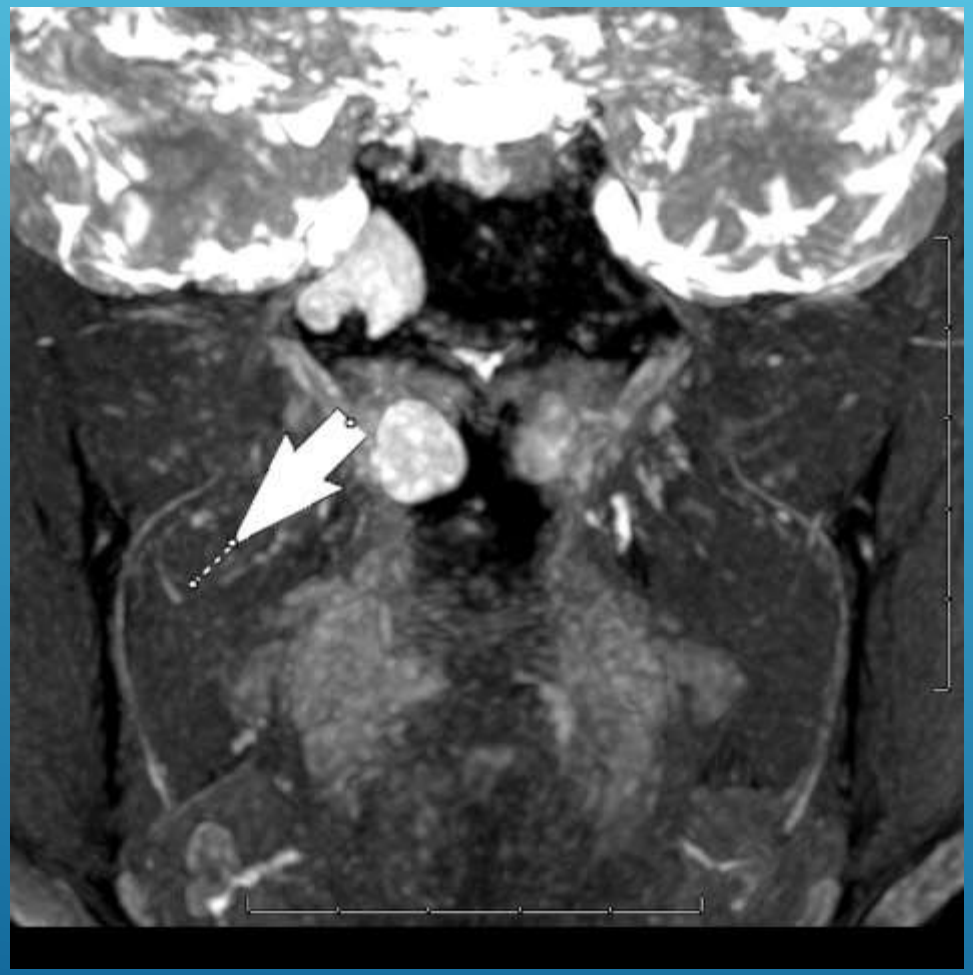

92832114
DOS = 7/21/17

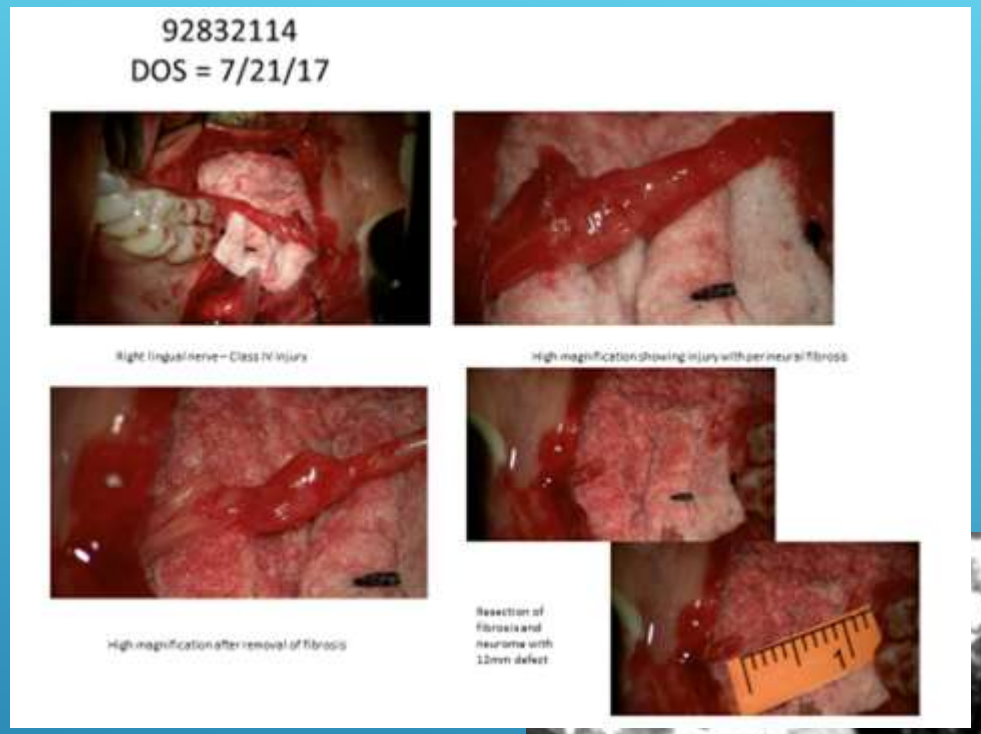

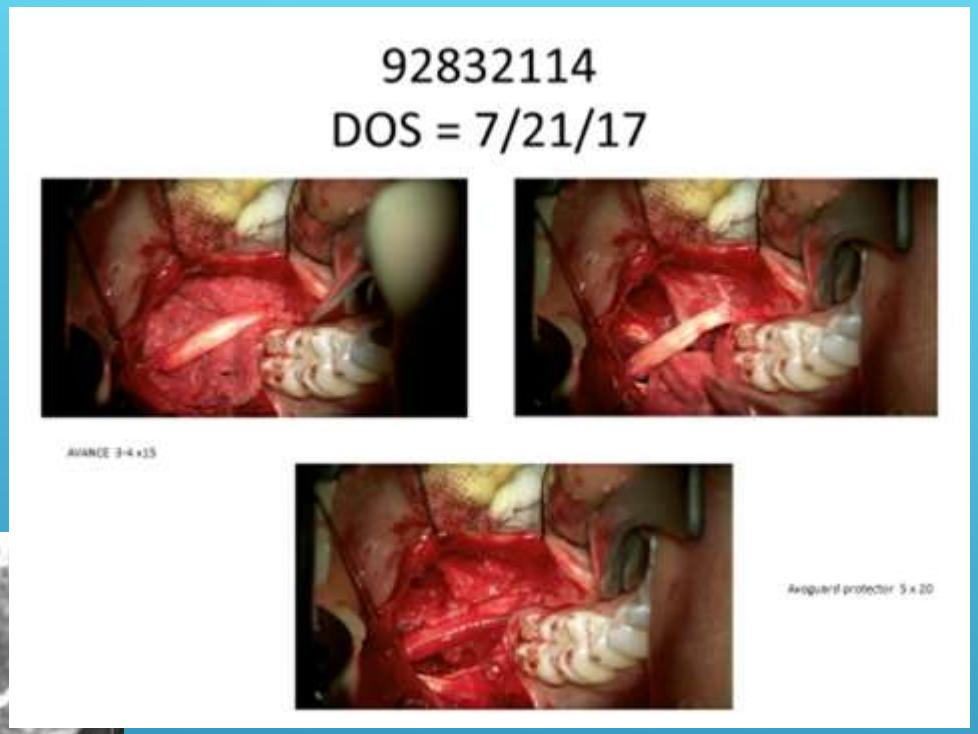

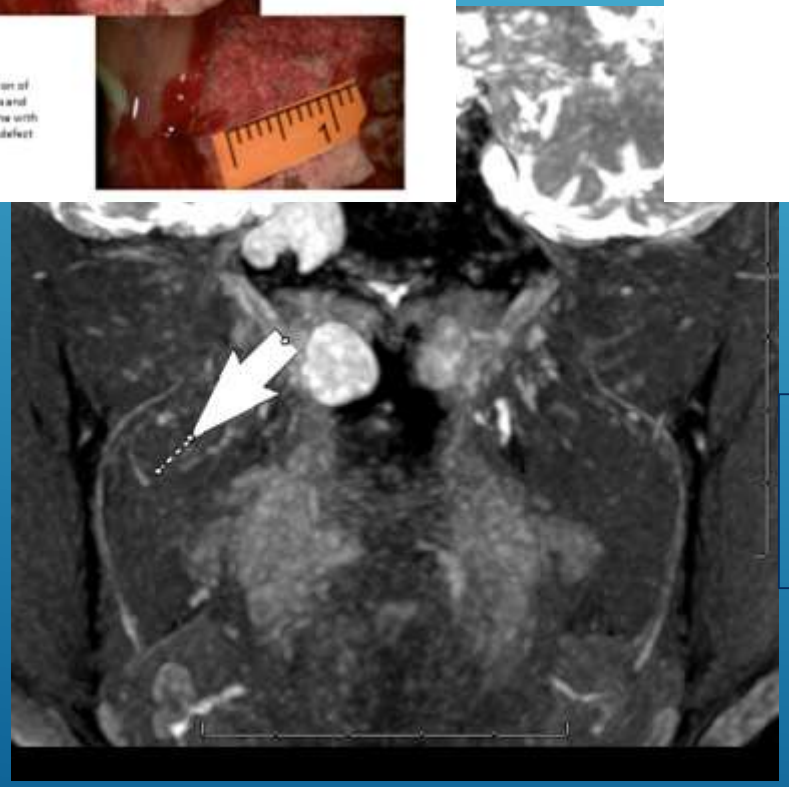

Lingual nerve
Class IV injury
following molar
tooth extraction
Neuroma in
continuity

Post nerve reconstruction

Young Female with 3 months s/p extraction third molar

PREV CT- MAY- ABSCESS

1 month s/p I&D left mandible with numbness lip/chin and tongue

MRN IN JULY- SEE SOMETHING?

DTI

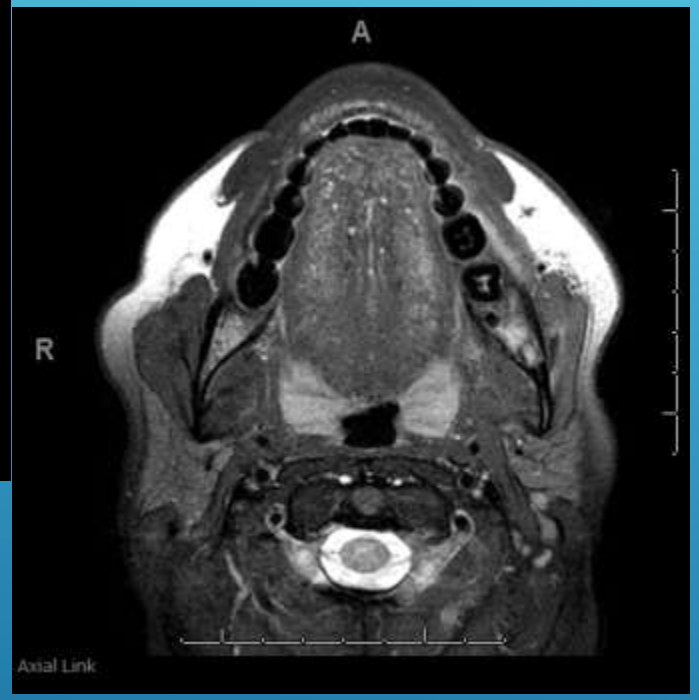

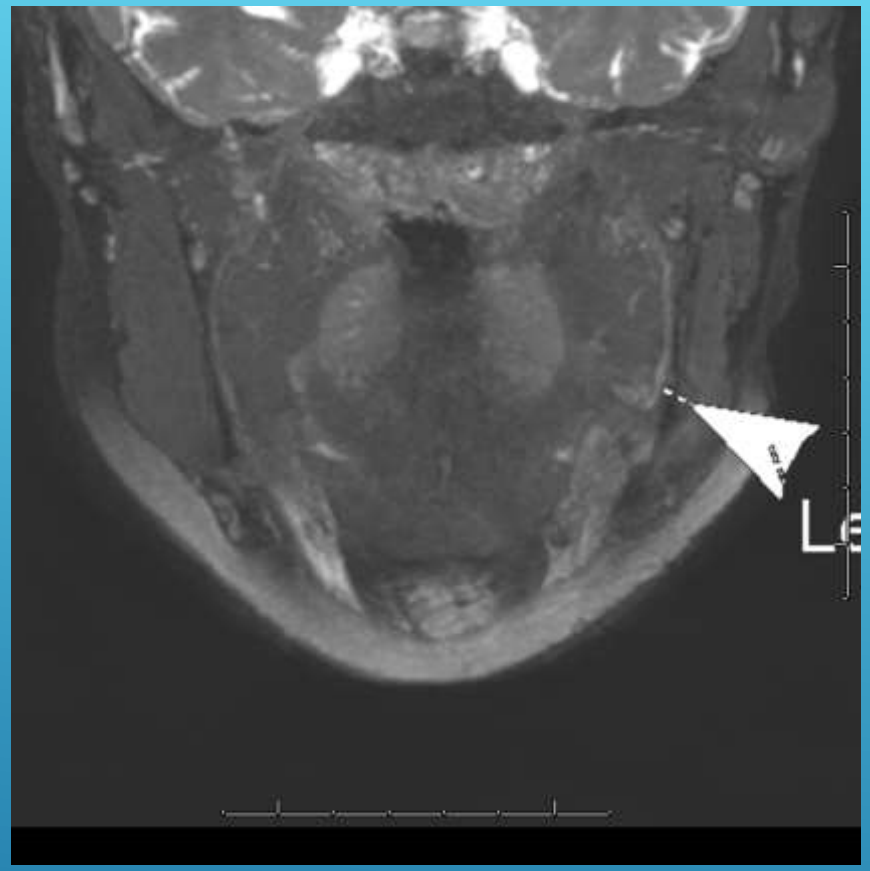

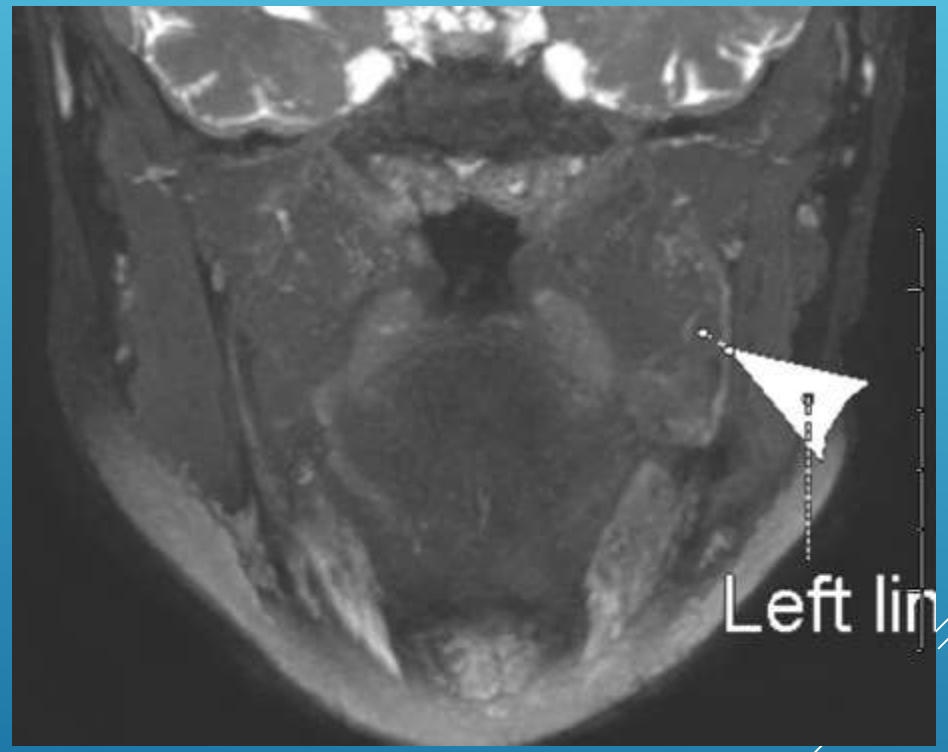

IAN AND LN– DIAG?

Diag- Class IV injury IAN
LN- Class IV/V- meaning bad neuroma

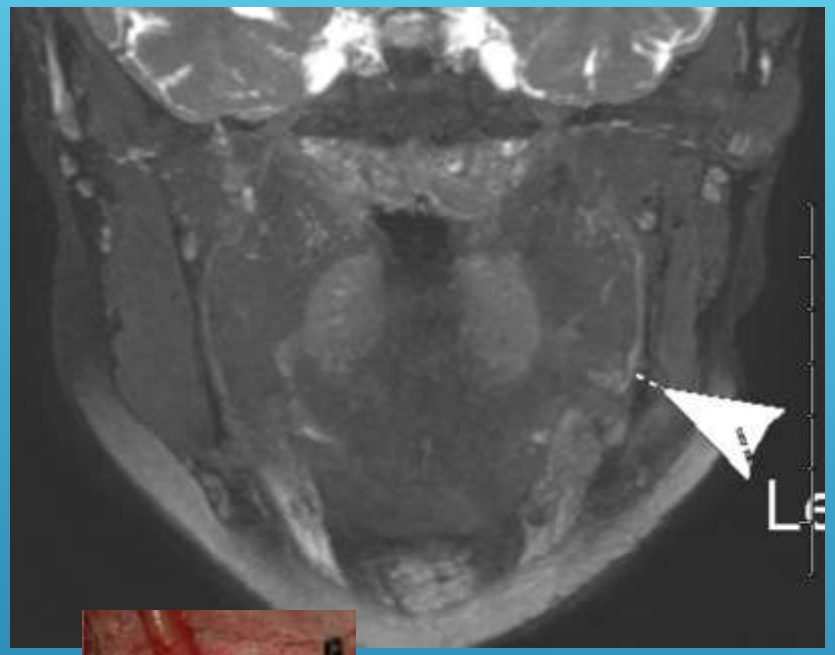

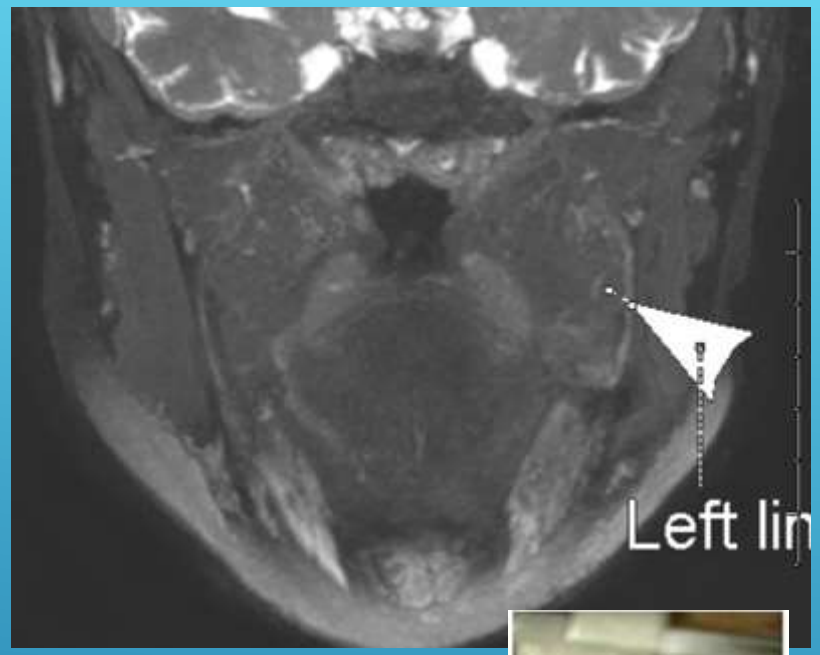

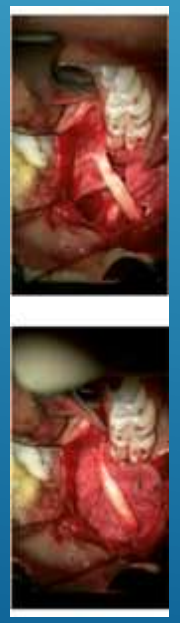

Molar tooth extraction injury- MR neurography and surgical correlation

Left- inferior alveolar nerve class IV injury

Right- lingual nerve class IV/V injury

8 MONTHS POST MOLAR TOOTH EXTRACTION- TONGUE PAIN AND DYSFUNCTION LEFT LINGUAL NERVE IN 64 Y/O MALE 90397190, DOS= 8/4/17

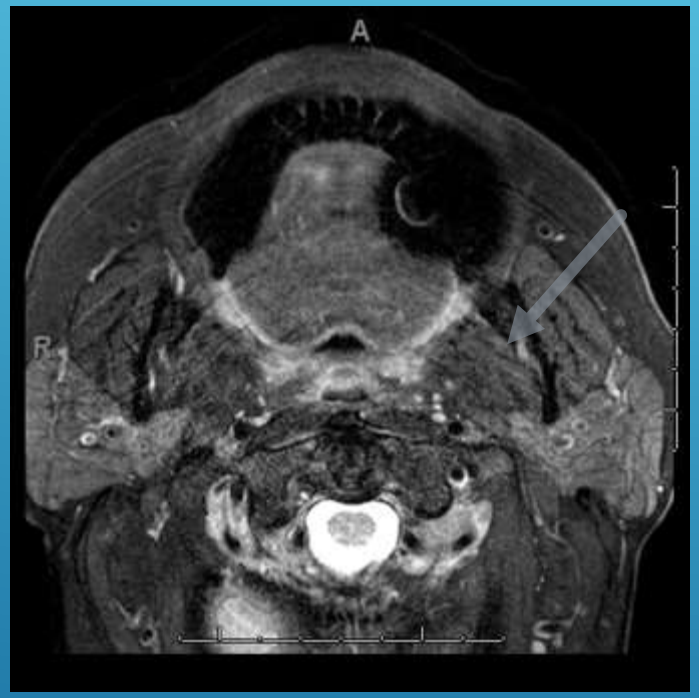

CAN YOU FIND THE LESION- UNFORTUNATELY PATIENT MOVED AND METAL IN ORAL CAVITY



HERE IT IS- PATIENT MOVED- SO IT IS CHALLENGING

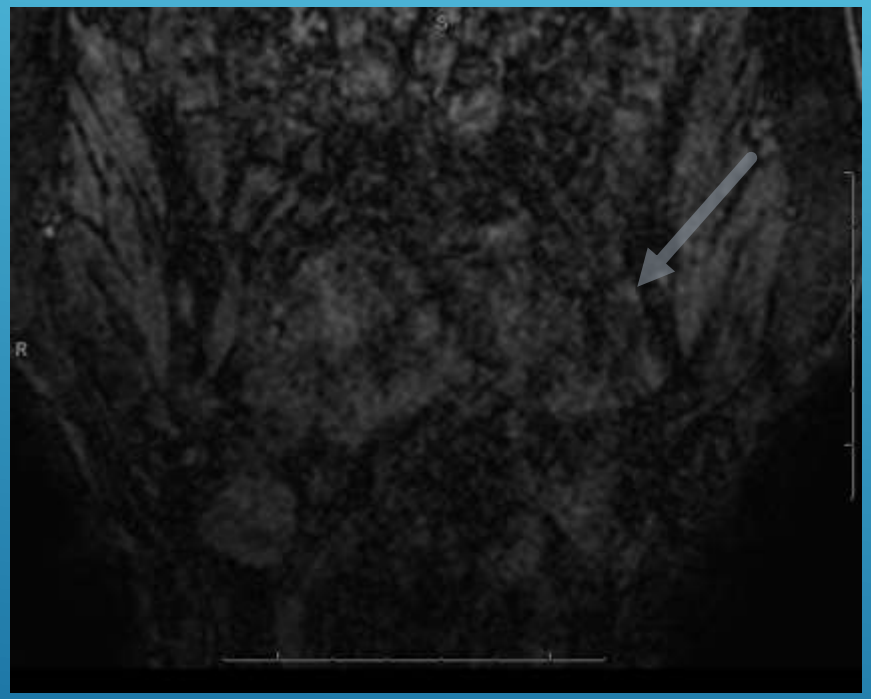

INFERIOR ALVEOLAR NERVES - NORMAL

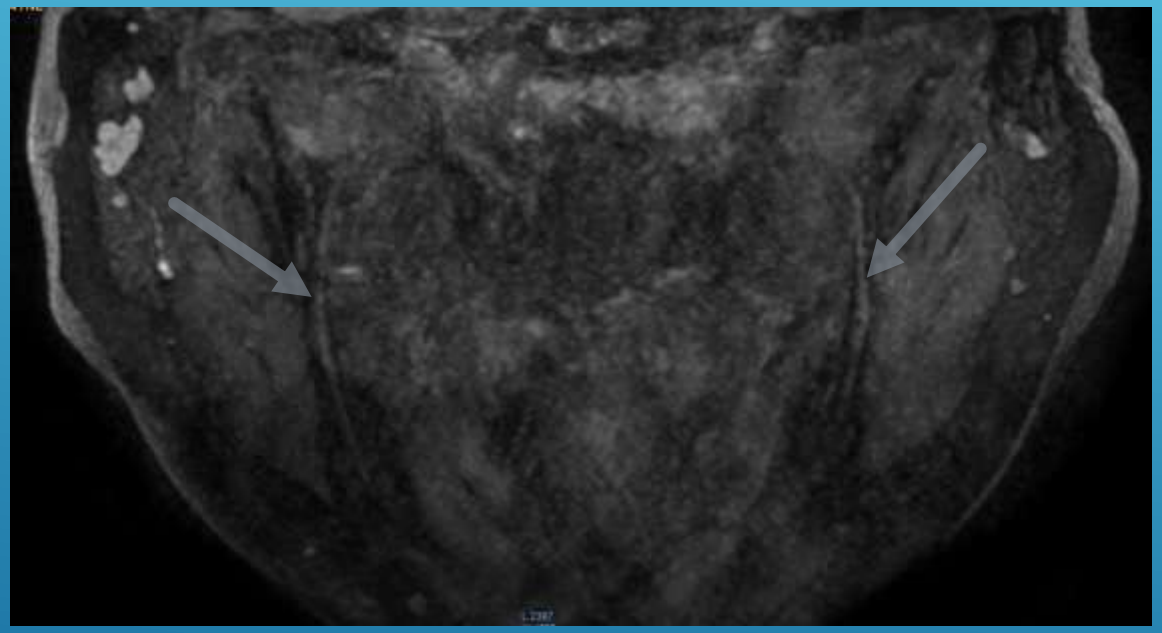

LINGUAL NERVE- NOTICE LATERAL NEUROMA IN CONTINUITY

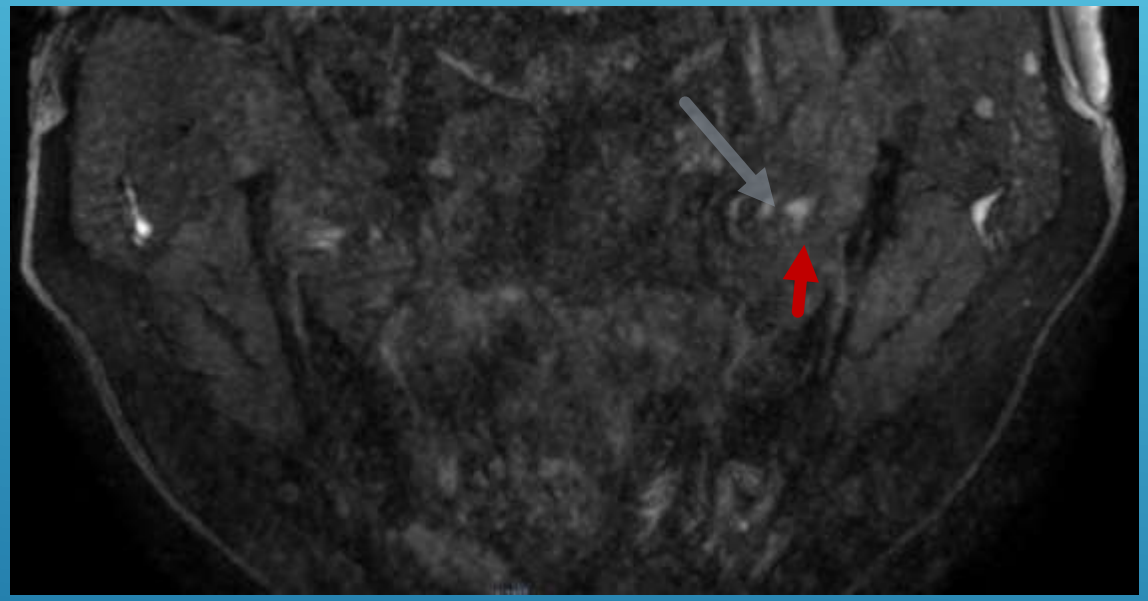

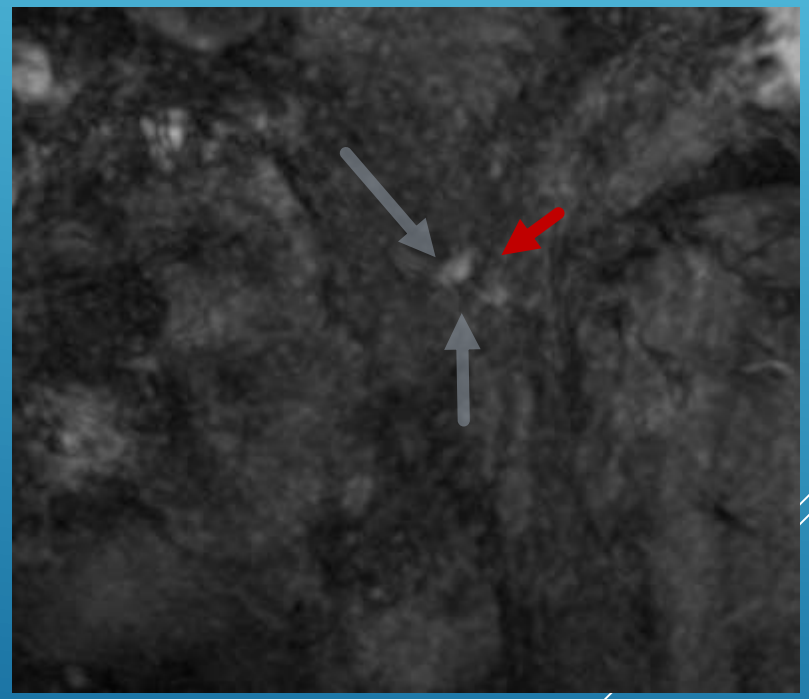

Sag recons- the lingual nerve neuromas are really well seen on Sag

Lateral neuroma in continuity

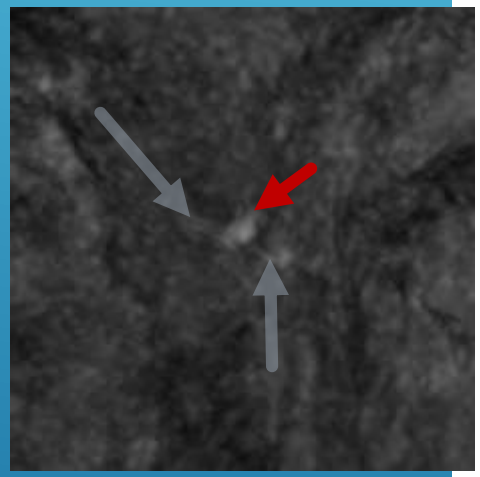

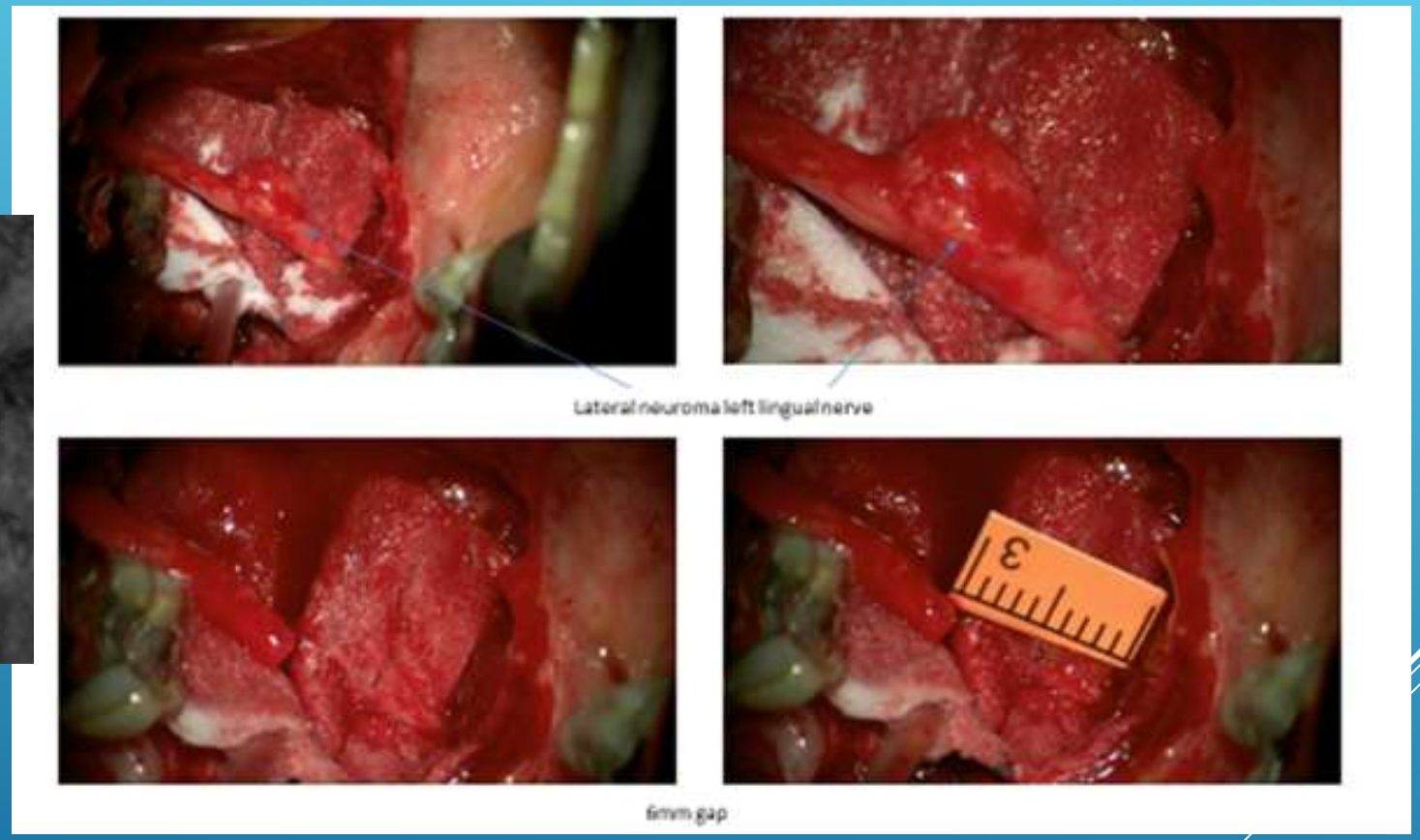

MAGNETIC RESONANCE NEUROGRAPHY ***(MRN)*** OF TRAUMATIC AND NON-TRAUMATIC PERIPHERAL TRIGEMINAL NEUROPATHIES ***(PTN)***

Zuniga JR, Mistry C, Tikhonov I, Dessouky R, Chhabra A: Magnetic Resonance Neurography of Traumatic and Non-Traumatic Peripheral Trigeminal Neuropathies. J Oral Maxillofac Surg 76:725-736, 2018, doi: 10.1016/j.joms.2017.11.007

- Inclusion Criteria
  - Patients seen at UTSW OMFS with neurosensory complaint who underwent clinical NST and consented to MRN evaluation for a suspected PTN in the second or third division of the trigeminal nerve.
- Exclusion Criteria
  - History of pre-existing bilateral IAN or LN pathology
- Demographics:
  - 60 patients (40 IAN and 20 LN)
  - Age 43 +/- 15 years (12-75 years old)
  - Numbness (25), pain (16), diminished/lost taste (19)

Distribution of ***Traumatic*** Peripheral Trigeminal Neuropathies by Nerve and Etiology

Nerve	Third Molar	Dental Implant	Benign Pathology	Orthognathic
IAN	10	11	7	1
LN	19	0	0	0

Distribution of ***Non-Traumatic*** Peripheral Trigeminal Neuropathies by Nerve and Etiology

Nerve	Dental injection	Non-invasive Endodontics	unknown
IAN	1	4	6
LN	1	0	0

UT SOUTHWESTERN MEDICAL CENTER

Traumatic (n= 48)

- IAN=28
  - 79% grade S3 to S4
  - NST – Sunderland III or IV
  - Neuropathic = 45%
  - Duration of sx = 13.61 months
- LN=19
  - 79% grade S0 to S2
  - NST – Sunderland IV and V
  - Neuropathic = 15%
  - Duration of sx = 5.5 months

Non-Traumatic (n=12)

- IAN = 11
  - 100% grade S3 to S4
  - NST = Sunderland < III
  - Neuropathic pain =50%
  - Duration of sx = 4.87 months
- LN = 1
  - S4
  - Sunderland 1
  - Neuropathic pain present
  - Duration of sx = 24 months

MAGNETIC RESONANCE NEUROGRAPHY ***(MRN)*** OF TRAUMATIC AND NON-TRAUMATIC PERIPHERAL TRIGEMINAL NEUROPATHIES ***(PTN)***

MRN correlation with NST

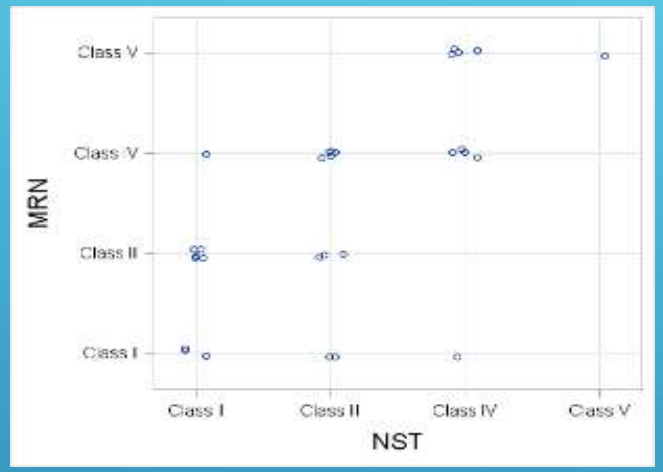

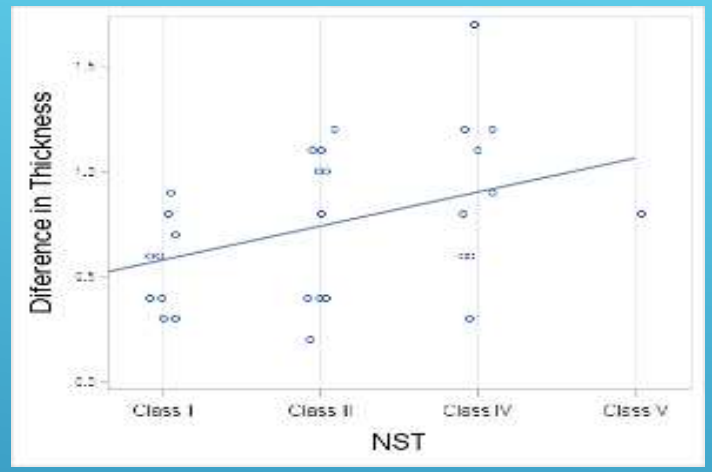

- Kappa 0.60
- PCC 0.66
- Accuracy 77%
- Sensitivity 90%
- Specificity 70%

MRN correlation with surgery

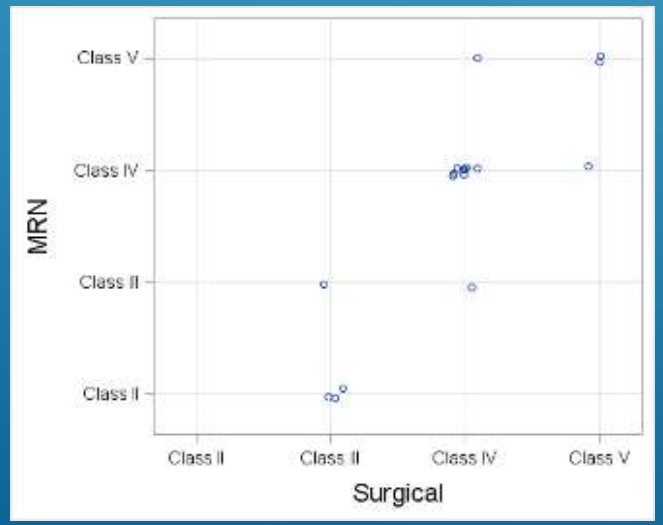

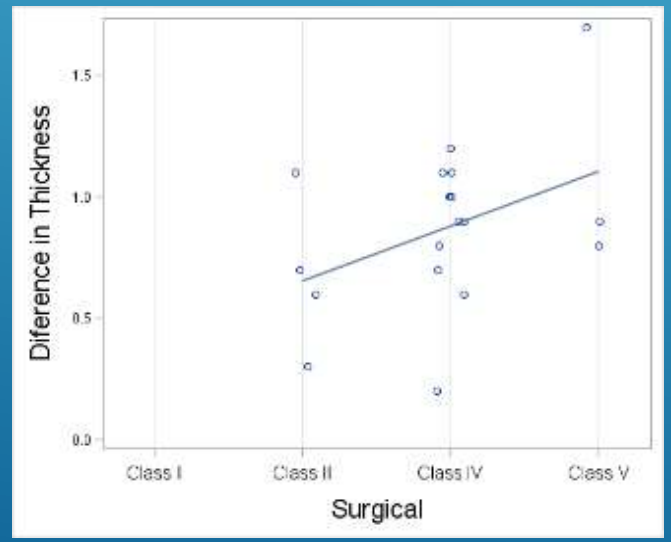

- Kappa 0.74
- PCC 0.90
- Accuracy 84%
- Sensitivity 93%
- Specificity 100%

26 surgeries
10 IAN
16 LN

UT SOUTHWESTERN MEDICAL CENTER

CONCLUSIONS

- MRN provides non-invasive information of the IAN and LN. Allows to map PTN injury and stratify nerve injury in traumatic and non-traumatic conditions
  - Non-traumatic = lower Sunderland levels, pain predominant symptom, MRN ranged from normal to Sunderland Class III with perineural fibrosis, mild thickening, entrapment or compression
  - Traumatic = higher Sunderland levels, sensory complaints with or without pain, MRN findings ranged from Sunderland Class III to V with no normals
- MRN has moderate to strong correlations with the NST levels/MRCS grading scores and the surgical findings.
  - Matched surgical findings 58%
  - Overestimated 4%
  - Underestimated 37%

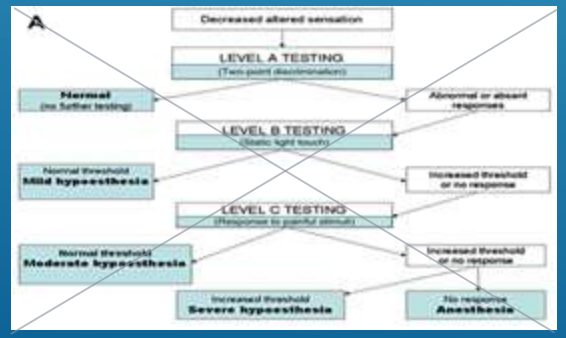

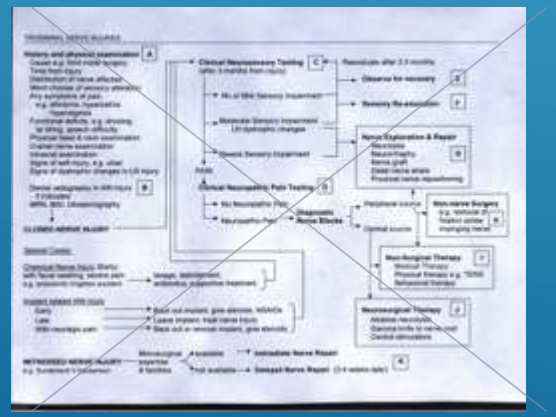

WHAT'S NEXT IN MRN STUDIES???
OUTCOMES!!!!!

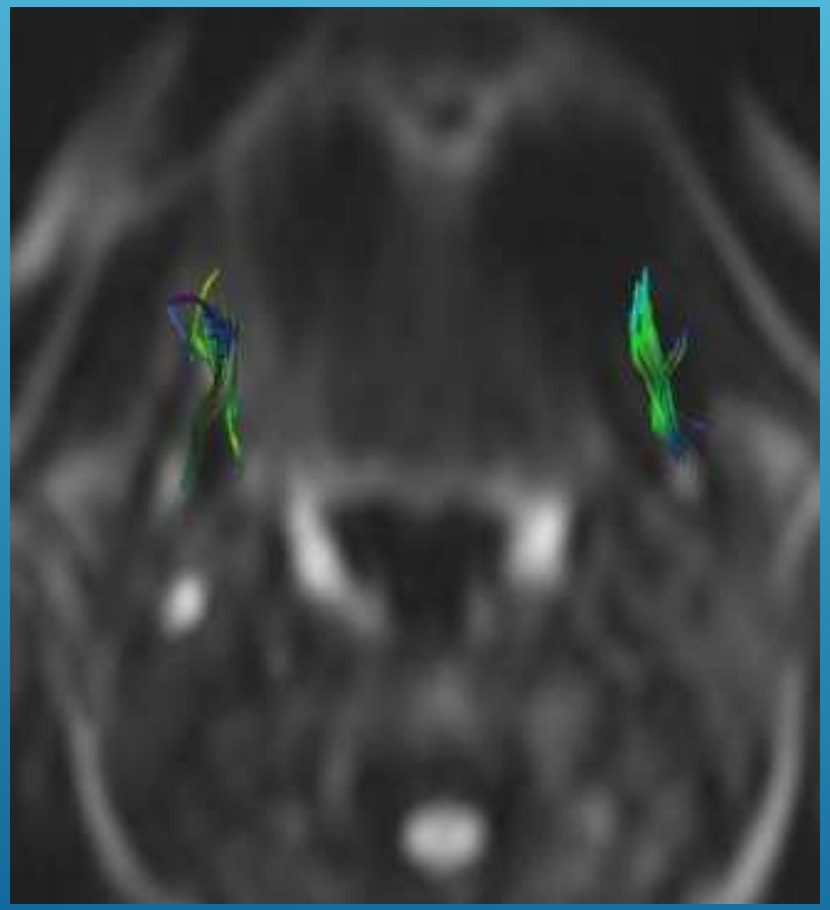

Post-op Imaging- Nerve Regeneration- sequential scans over 6 months.. showing ulnar nerve fascicular growth

Fluid filled tube

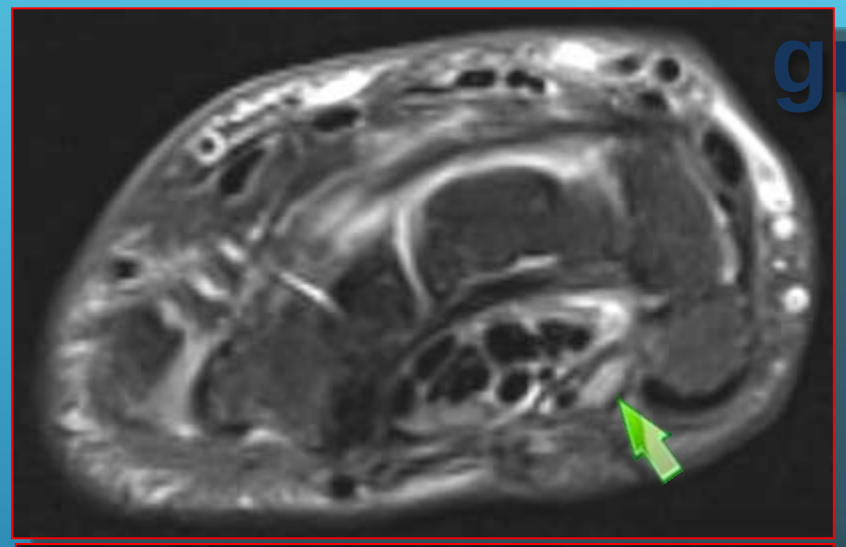

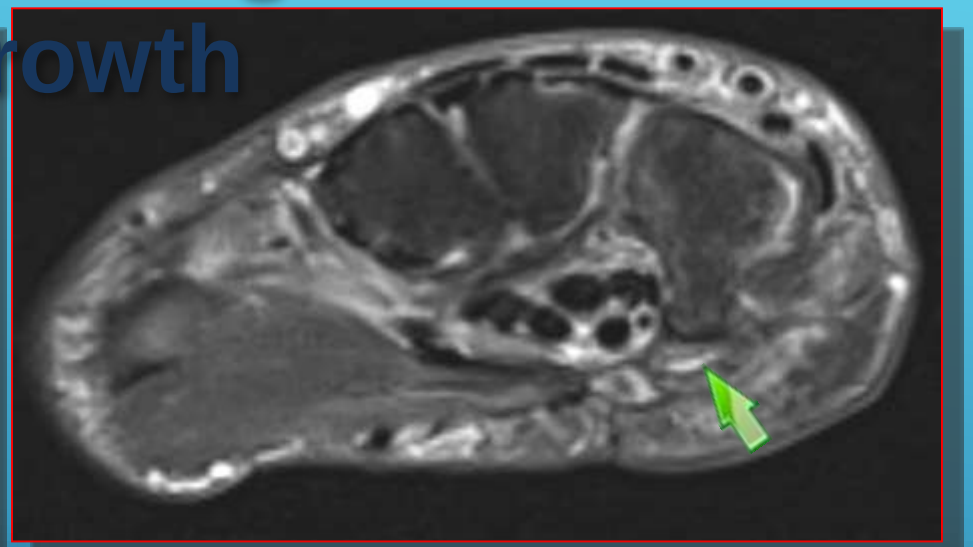

Early nerve sprouting

Fascicle formation sprouting

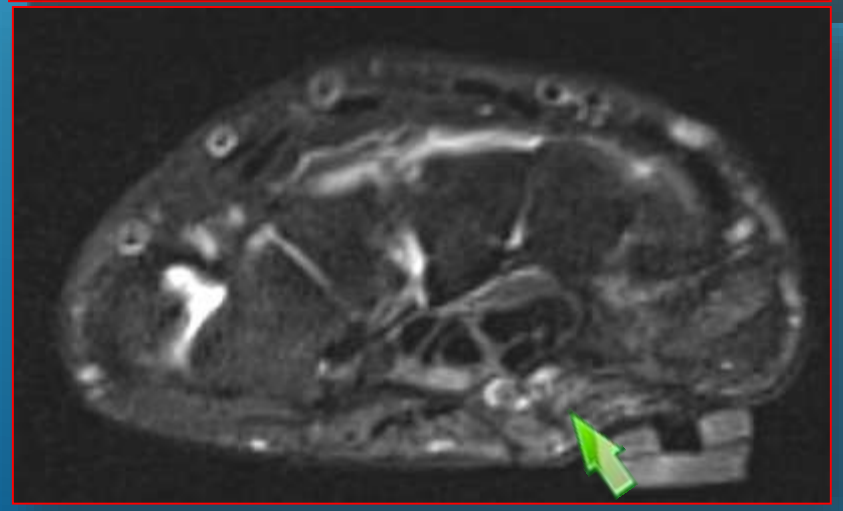

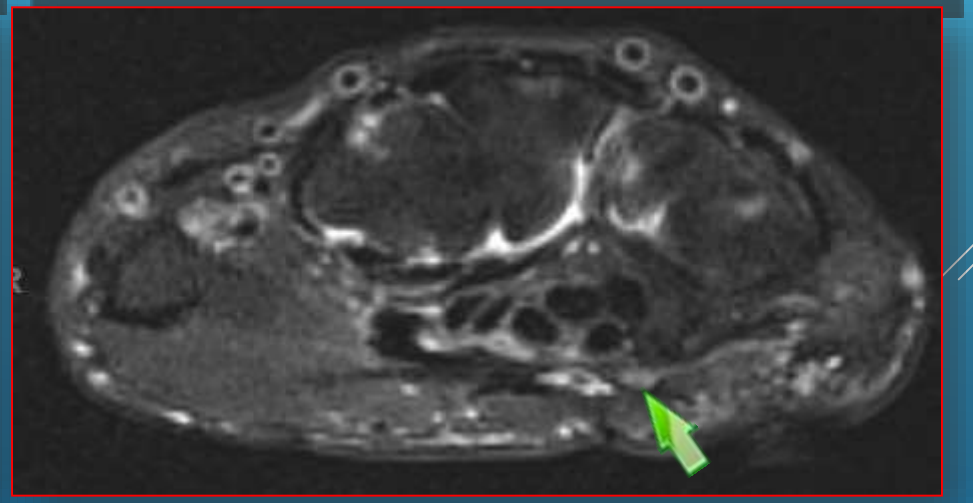

Fascicle formation and distal growth

Follow-up- ulnar nerve functional

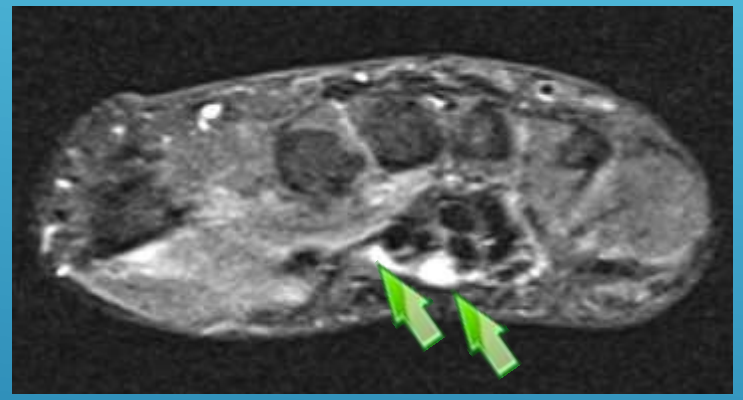

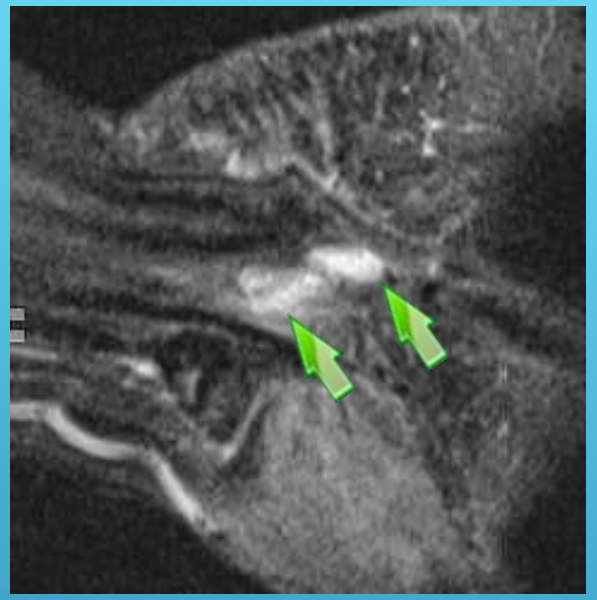

Post-op failure- fluid filled nerve tubes

Re-exploration operative image

No nerve connection- post op neuromas

YOUNG FEMALE 1-1/2 YR S/P INJURY RIGHT INFERIOR ALVEOLAR NERVE

Molar tooth again

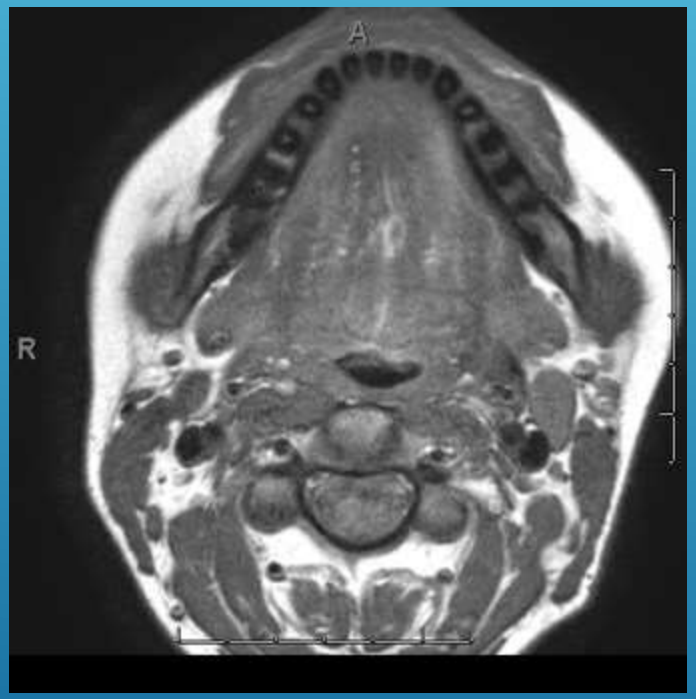
A
R

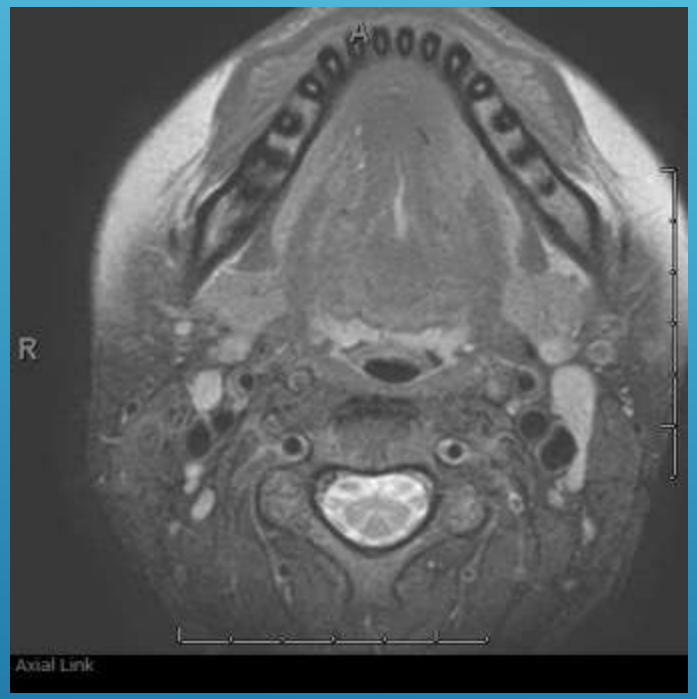
A
R
Axial Link


A
R


A
R
Axial Link

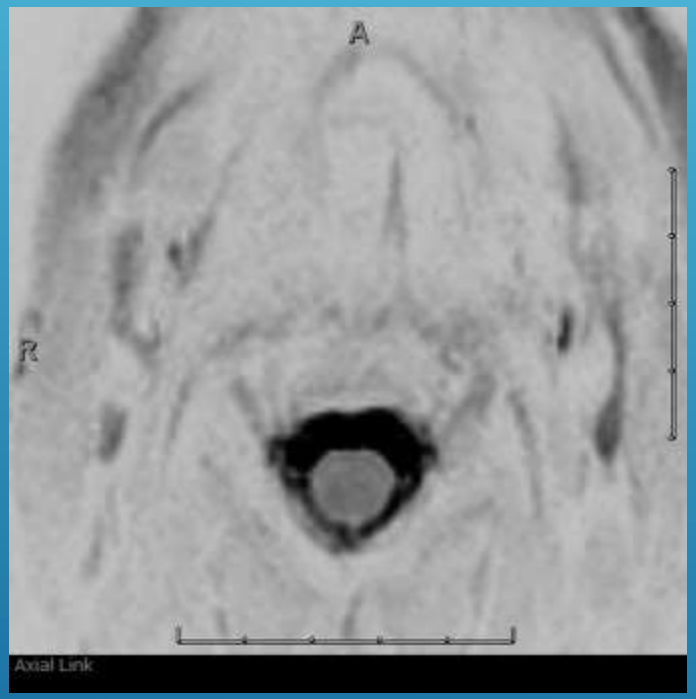
A
R
Axial Link

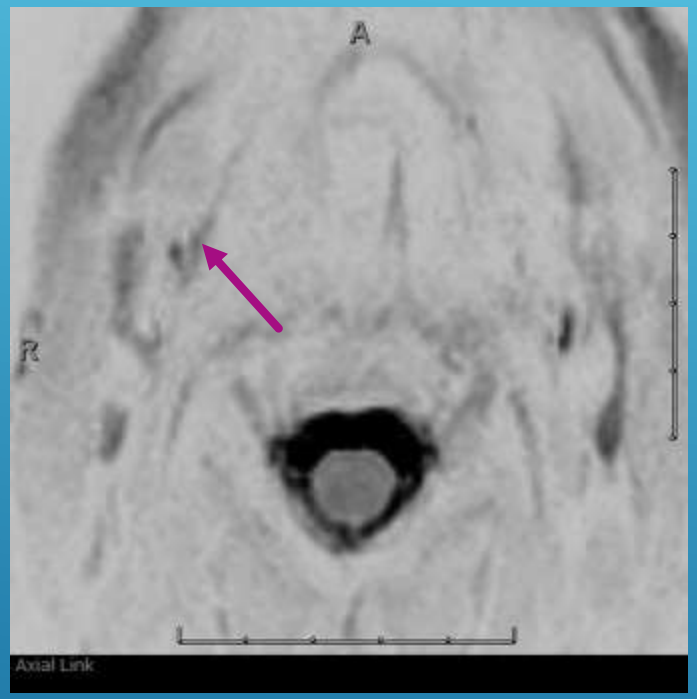
A
R
Axial Link

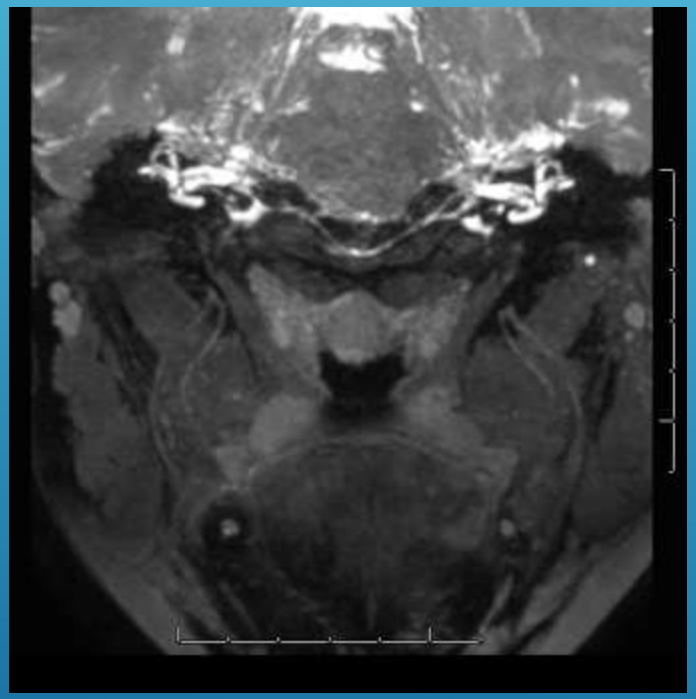

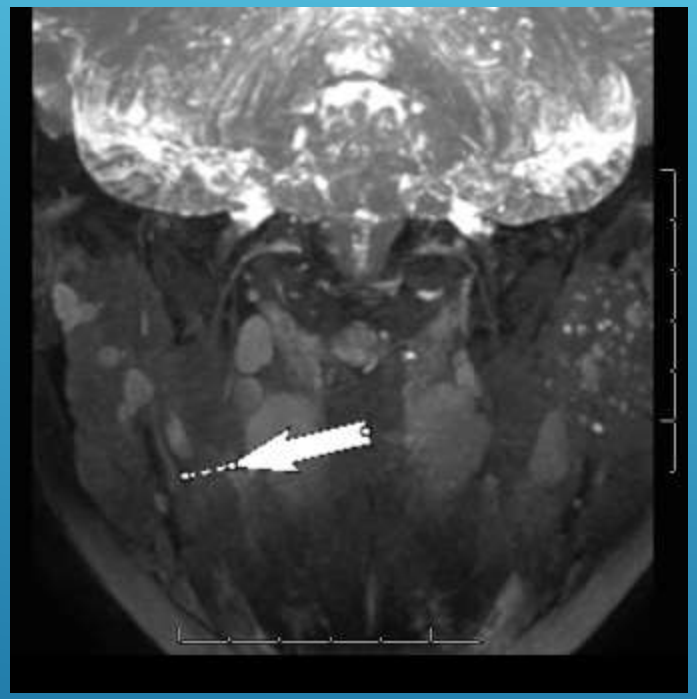

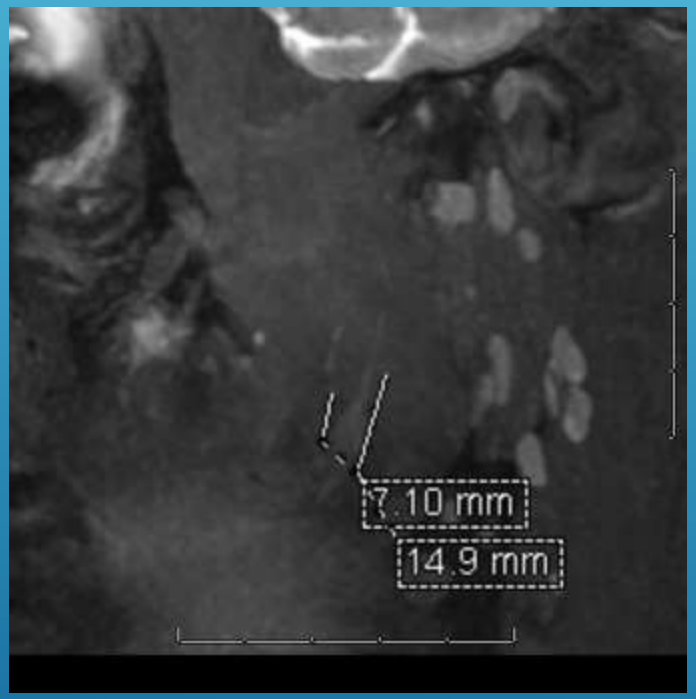
7.10 mm
14.9 mm

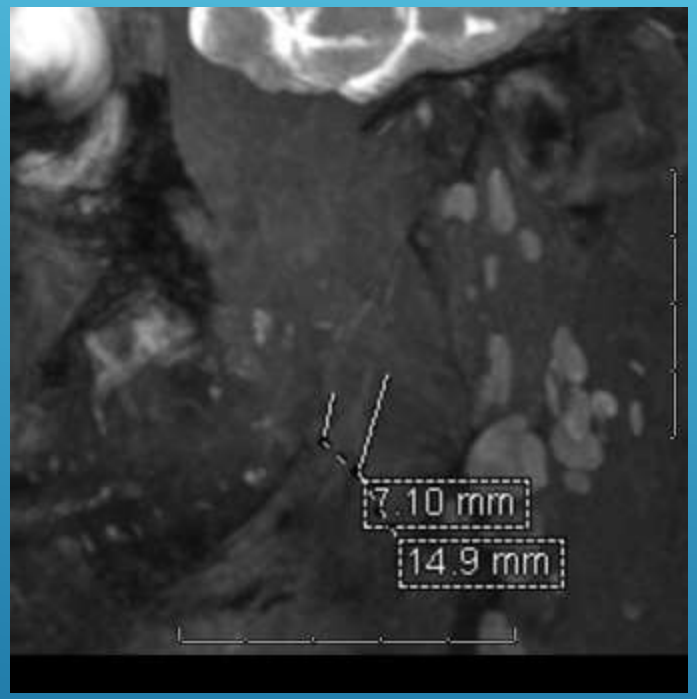
7.10 mm
14.9 mm

93553092
DOS = 5/25/18

Right IAN low mag at 3rd molar site

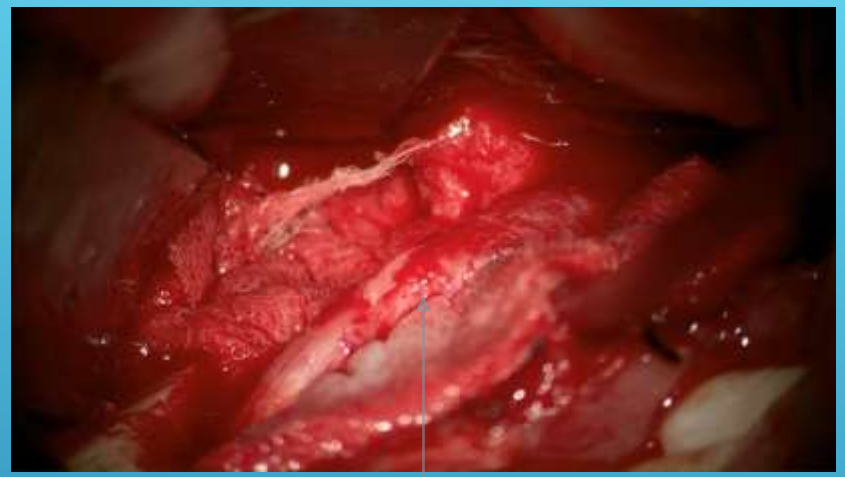

Right IAN high mag at 3rd molar site with injury

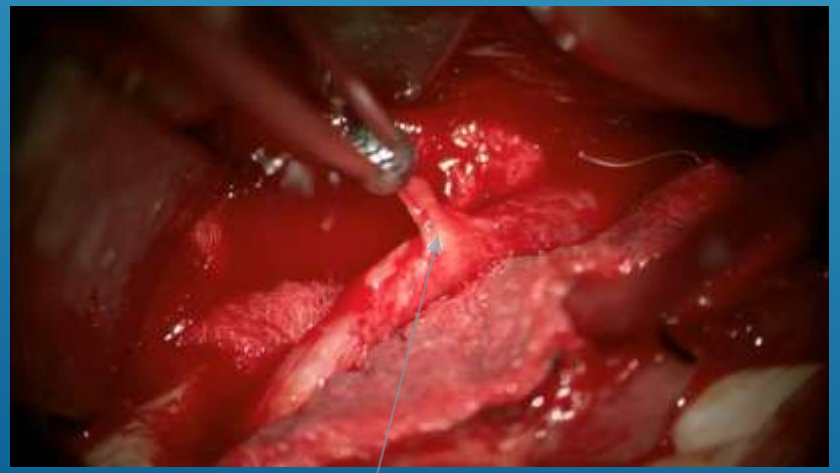

Site of injury

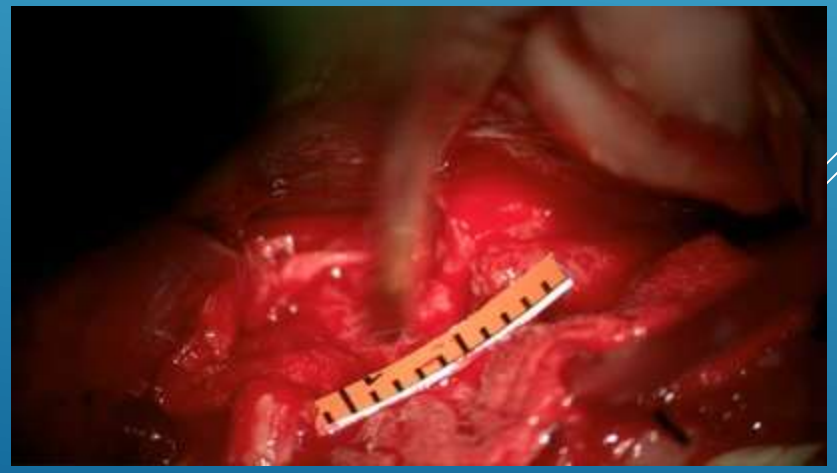

After resection of neuroma-in-continuity, 8mm gap

93553092
DOS = 5/25/18

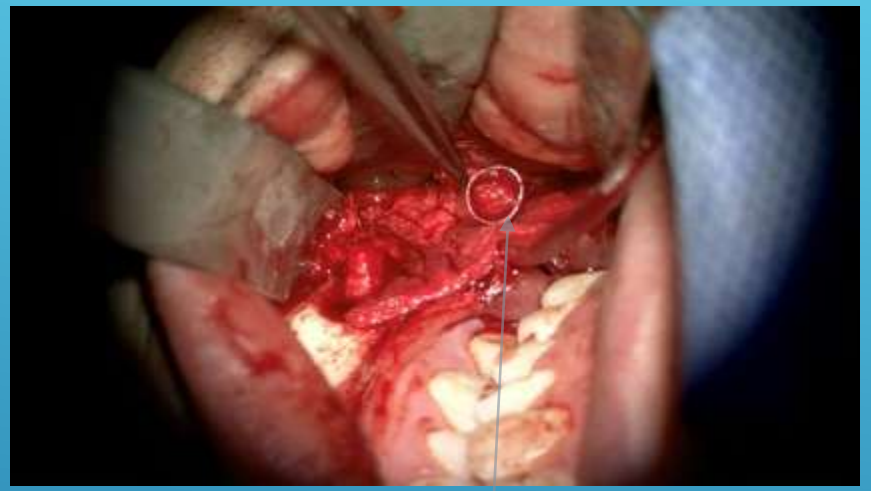

Connector attached to proximal end

Graft insert and attached to distal end for best alignment of fascicles

Completed case with axoguard protectors/connectors

Postop nerve regeneration-

Right IAN partial regeneration.
Left normal IAN in face

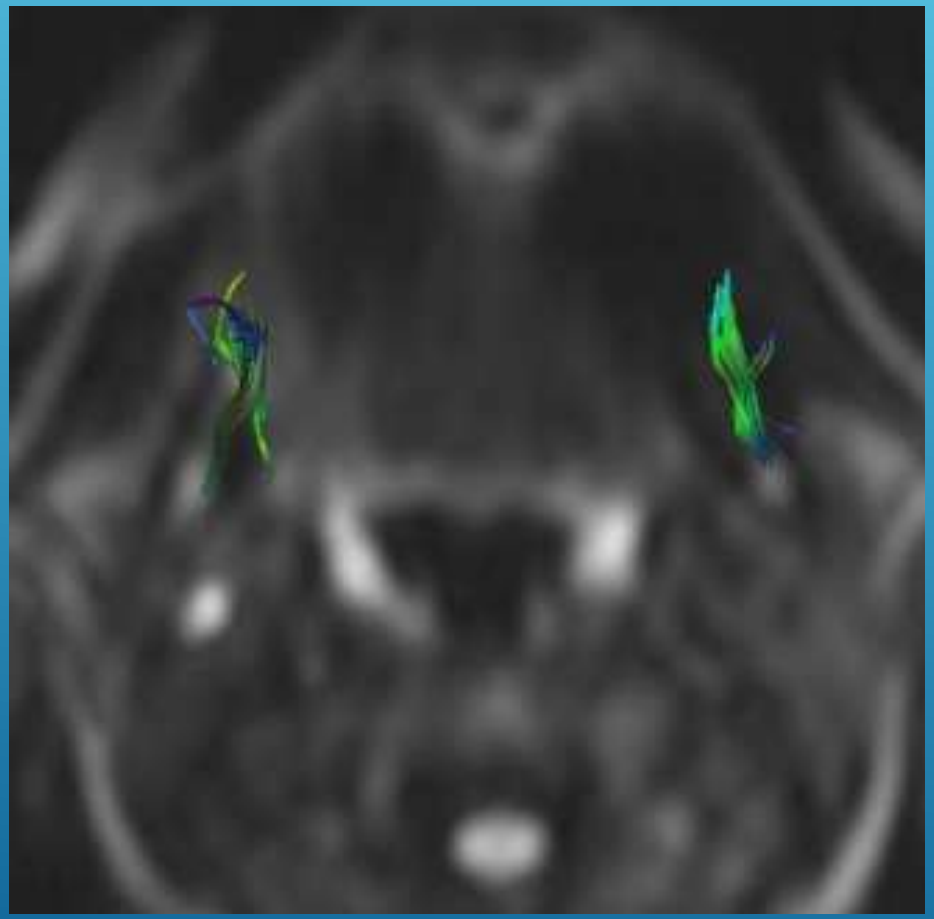

Diffusion Tension Imaging
September, 2018

Regenerating through Allograft
a. haphazard sprouting
b. anisotropy present
c. double back?
d. reduced volume
e. no neuroma

Many Thanks!

2018 Annual *Meeting*

Florida Society of Oral and Maxillofacial Surgeo

UT SOUTHWESTERN MEDICAL CENTER